

ALESSANDRO MARIA MARRA¹ , CARLO MARIA ROSSI^{2,3} , MARIO ANDREA PIGA⁴ ,
GIANLUCA MORONCINI^{4,5,6} , MARIA BEATRICE BILO^{6,7} 

Eosinophil-associated diseases: the allergist's and clinical immunologist's perspective

¹UO Pneumology, ASST Rhodense, Garbagnate Milanese Hospital, Milan, Italy

²Department of Internal Medicine and Therapeutics, University of Pavia, Pavia, Italy

³First Department of Internal Medicine, IRCCS San Matteo Hospital Foundation, Pavia, Italy

⁴National PhD Course in Precision Medicine in Rare Diseases, University of Palermo, Palermo, Italy

⁵Medical Clinic, Department of Internal Medicine, Marche University Hospital, Ancona, Italy

⁶Department of Clinical and Molecular Sciences, Università Politecnica delle Marche, Italy

⁷Allergy Unit, Department of Internal Medicine, University Hospital Ospedali Riuniti di Ancona, Ancona, Italy

KEY WORDS

Eosinophilia; hypereosinophilia; eosinophilic disorders of gastrointestinal tract (EGID); eosinophilic granulomatosis with polyangiitis (EGPA); hypereosinophilic syndrome (HES).

Corresponding author

Alessandro Maria Marra

ASST Rhodense

viale Forlanini 95

20024 Garbagnate Milanese, Milan, Italy

ORCID: 0009-0001-1860-2726

E-mail: alessandromarra@hotmail.com

Doi

10.23822/EurAnnACI.1764-1489.339

IMPACT STATEMENT

Eosinophilic disorders encompass a broad range of heterogeneous conditions. Allergists and clinical immunologists have a deep knowledge of type 2-eosinophilic inflammation. They can better refine the eosinophilia workup and make the most appropriate diagnosis.

Summary

Eosinophil-associated diseases (EADs) refer to heterogeneous conditions in which eosinophils are believed to play critical pathological roles. They encompass common respiratory conditions, such as asthma, chronic rhinosinusitis with nasal polyps (CRSwNP), less common primary eosinophilic disorders of gastrointestinal tract, and rare conditions including eosinophilic granulomatosis with polyangiitis (EGPA) and hypereosinophilic syndrome (HES). A literature search was carried out in January 2024 in the MEDLINE and Scopus databases using the PubMed search engine (PubMed, National Library of Medicine, Bethesda, MD). A diagnostic workup is proposed. From allergist's point of view, we focused the review on 4 groups of eosinophilic disorders of specific interest. Our increased understanding of type 2 inflammation and biology has recently led to development of highly effective precision targeted therapies that are now approved for a growing number of eosinophilic disorders. Novel targeted biologics have a major impact on treatment strategies and have resulted in major advances in our understanding of the pathogenesis of these disorders. In the context of EADs, according to the heterogeneity of eosinophilic disorders, a multidisciplinary approach should be adopted. Allergists and clinical immunologists play an important role as they have a clear understanding of the eosinophilic inflammation and the role of cytokines and are trained to recognize and characterize type 2 (T2) inflammation and its associated pathologies.

Introduction

Over the past two decades, it was discovered that a range of inflammatory diseases involving several organ systems with elevated

eosinophil counts in blood and/or tissue was primarily driven by abnormal regulation of the number and activation state of eosinophils. Eosinophil-associated diseases (EADs) refer to these heterogeneous conditions in which eosinophils are believed to play critical patho-

logical roles (1). EADs encompass common respiratory conditions such as asthma, (mostly eosinophilic) chronic rhinosinusitis with nasal polyps (CRSwNP), less common eosinophilic disorders of the gastrointestinal tract (EGID), and rare conditions including eosinophilic granulomatosis with polyangiitis (EGPA) and hypereosinophilic syndrome (HES) (2). Despite remarkable progress in understanding pathophysiologic mechanisms of eosinophilic disorders, gaps remain in this very heterogeneous group of diseases. While common EADs are well-characterized, others are extremely rare conditions and have very heterogeneous clinical presentations. The awareness of EADs varies among healthcare professionals. Therefore, patients with EADs face substantial disease burdens due to the severity of their illness and associated disease flares, and a range of healthcare barriers, including delayed times to referral, diagnosis, and treatment, often involving repeated visits to multiple clinical subspecialties (3), therefore, a multidisciplinary approach should be adopted. In the context of a multidisciplinary team, allergists and clinical immunologists play an important role. Indeed, their deep knowledge of type 2 (T2)-eosinophilic inflammation allows them to have an holistic view of hypereosinophilic disorders. They are trained to recognize and characterize type 2 inflammation and its associated pathologies (**figure 1**). The aim of this review is to highlight the state of the art regarding the knowledge of blood eosinophilia and hypereosinophilia (proposing a diagnostic workup) and the most important eosinophil-associated diseases focusing particularly on those where significant advancements have been made in targeted therapy towards type 2 inflammation in recent years.

Methods

A literature search was carried out in January 2024 in the MEDLINE and Scopus databases using the PubMed search engine (PubMed, National Library of Medicine, Bethesda, MD). Keywords in the

query included: “Eosinophilia, hypereosinophilia eosinophilic disorders of gastrointestinal tract (EGID), eosinophilic granulomatosis with polyangiitis (EGPA), hypereosinophilic syndrome (HES)”. The first search was limited to articles published over the last fifteen years. Some older papers of particular interest were subsequently included. A narrative review was performed based on the relevant literature, including original articles and reviews of interests. The reference lists of all articles were scanned for references not identified in the initial research. We favored papers with the most updated data regarding the incidence, prevalence of diseases and new therapeutic perspectives targeting type 2 inflammation. Regarding blood eosinophilia, we searched the literature to propose a diagnostic workup for persistent unexplained eosinophilia or hypereosinophilia to assist clinicians in directing and diagnosing any related pathologies more effectively. The research was performed exclusively by allergists and clinical immunologists to consider their role as profound experts and guides for other specialists in the study of blood eosinophilia and type 2 inflammation. From allergist's point of view, we focused on 4 groups of eosinophilic disorders of specific interest which are characterized by eosinophilic and type 2 inflammation: eosinophilic asthma and CRSwNP, eosinophilic disorders of the gastrointestinal tract (EGID), EGPA and HES.

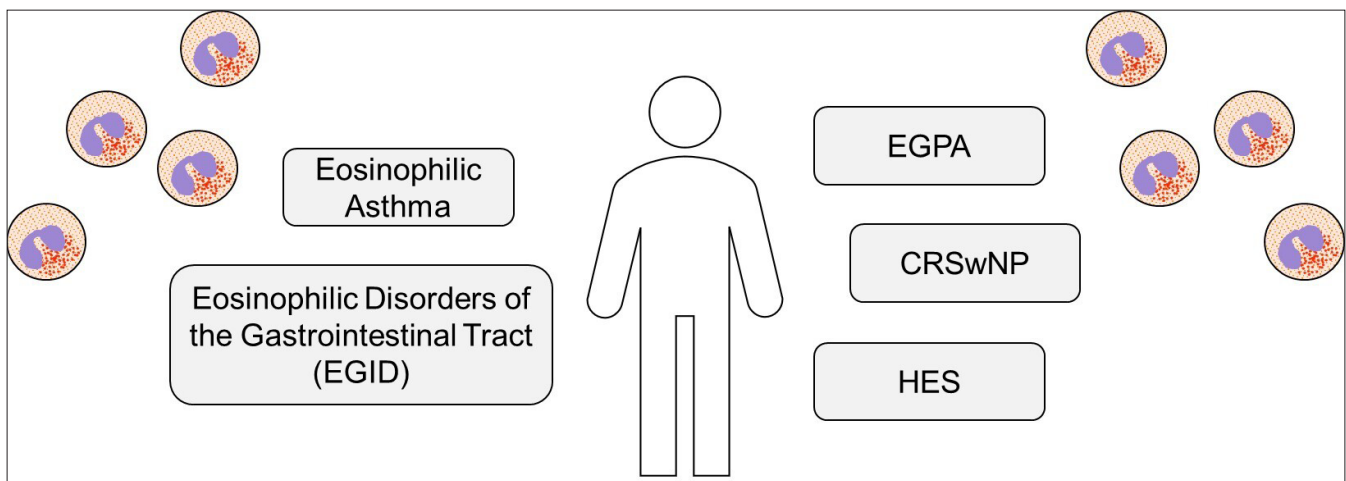
Results

106 papers were selected, included and cited. Starting from the literature, we examined the diagnostic workup of blood eosinophilia and hypereosinophilia and subsequently the spectrum of eosinophilic disorders of interest.

Diagnostic workup of eosinophilia

Peripheral blood eosinophilia can occur as absolute blood eosinophilia ($> 0.5 \times 10^9/L$), relative blood eosinophilia ($> 6\%$ in

Figure 1 - The spectrum of eosinophilic diseases: allergist's point of view.

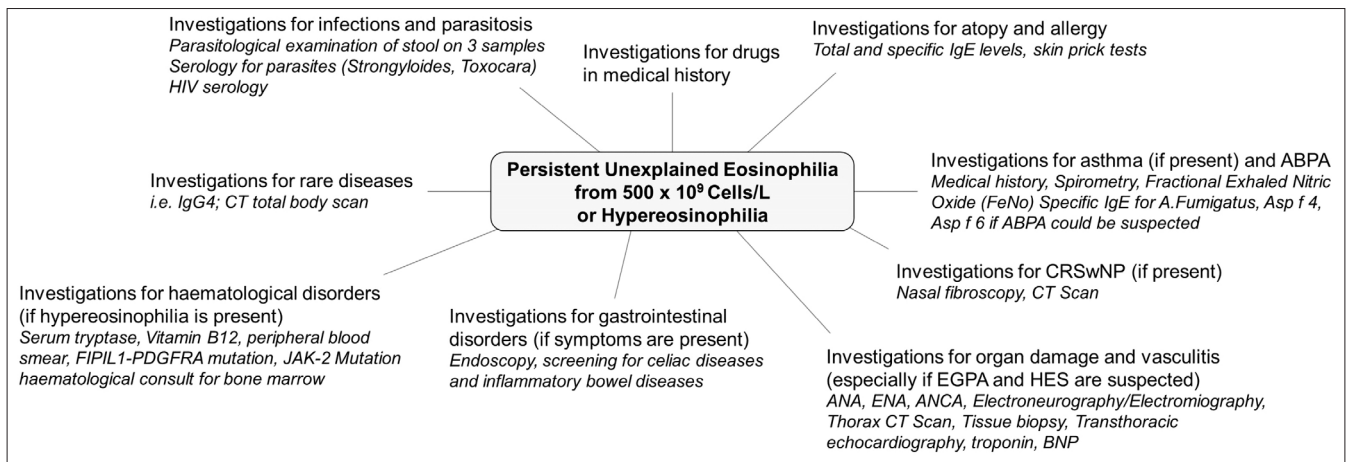


differential counts) or combined absolute and relative eosinophilia (absolute $> 0.5 \times 10^9/L$ and $> 6\%$). Absolute peripheral blood eosinophilia can be classified into mild eosinophilia ($0.5-1.49 \times 10^9/L$), moderate hypereosinophilia ($1.5-5.0 \times 10^9/L$), and severe hypereosinophilia ($> 5.0 \times 10^9/L$) (4). In the original definition of hypereosinophilia (HE), "persistent" was defined as absolute eosinophil count (AEC) $> 1.5 \times 10^9/L$ for at least 4 weeks (5). The World Health Organization (WHO) recently also confirmed a 4-week interval as reasonable observation period (6). However, during the Year 2021 Working Conference, this interval was once again debated. Many authors agreed that the term "persistent" should apply to HE recorded on at least 2 occasions with a minimum "time-interval" of 2 weeks (4). The diagnostic approach to a wide range of eosinophilic syndromes is facilitated by the well-established division into primary and secondary (reactive) eosinophilic states (7) (**table I**) which have been further refined according to updated classifications (8, 9). Not only HE but also eosinophilia can be related to systemic diseases: recent ACR/EULAR 2022 criteria for ANCA-associated vasculitides include for diagnosis of EGPA a minimum eosinophil count $\geq 1 \times 10^9/liter$ (10). Recently, new refined diagnostic criteria and classification of primary eosinophil disorders was proposed (4, 11) (**table I**). Virtually any organ system may be susceptible to the effects of sustained eosinophilia but is very important to classify eosinophilia into the right diagnostic path, dividing the primary causes from the secondary causes. Secondary eosinophilia has numerous causes that may require diagnostic evaluation by a lot of sub-specialty consultants. In developing countries, eosinophilia most commonly derives from infections, particularly tissue-invasive parasites (12). Allergy/atopy and hypersensitivity conditions, drug reactions (for instance drug eruption with systemic symptoms – DRESS – Syndrome), collagen-vascular disease and vasculitides like eosinophilic granulomatosis with polyangiitis (EGPA) granulomatosis with polyangiitis, systemic lupus erythemato-

sus, pulmonary eosinophilic diseases like idiopathic acute or chronic eosinophilic pneumonia or allergic bronchopulmonary aspergillosis (ABPA), allergic gastroenteritis (with associated peripheral eosinophilia), and metabolic conditions such as adrenal insufficiency are diagnostic considerations in the appropriate clinical context (13-15). Eosinophilic disorders are numerous and have different etiologies, hematological conditions (for example, lymphocytic and myeloproliferative hypereosinophilic syndromes, the latter being characterized by FIP1L1 fusion genes) or conditions that only occasionally present with eosinophilia but can have overlapping features with EGPA (such as HIV infection or IgG4-related disease) should also be considered (16). Non-myeloid malignancies may be associated with secondary eosinophilia that results from the production of cytokines, such as interleukin-3 (IL-3), IL-5, and GM-CSF, which promote eosinophil differentiation and survival. For example, these cytokines may be elaborated from malignant cells in T-cell lymphomas, Hodgkin lymphoma, and acute lymphoblastic leukemias (17, 18). Rare conditions associated with eosinophilia include familial eosinophilia whose genetic basis remains largely unknown (recent association with a CMTM3 mutation) hyper IgE syndrome, Omenn syndrome, episodic angioedema, and eosinophilia (Gleich's syndrome), and eosinophilia-myalgia syndrome (possibly related to tryptophan ingestion or of historical interest, the epidemic of toxic-oil syndrome) (5, 19). Detailed travel history and repeated ova and parasite testing, stool culture, and antibody testing for specific parasites (for example strongyloidiasis) are paramount to identifying infectious etiologies in the appropriate clinical context. Elevated immunoglobulin E levels is a nonspecific finding that is mostly seen in reactive conditions (infectious, allergic "including fungal sensitization/ABPA", vasculitis, and lymphocyte-variant HES), whereas its elevation is variable in patients with clonal disorders (20). Additional laboratory testing can be useful such as troponin T or I, anti-neutrophil antibodies (ANA), anti-neutrophil cytoplasmic

Table I - Eosinophilia, hypereosinophilia and types of hypereosinophilia.

Condition	Definition/Features
Blood Eosinophilia	Eosinophil count between 0.5 and $1.5 \times 10^9/L$ eosinophils
Hypereosinophilia (HE)	Eosinophil count $> 1.5 \times 10^9/L$ on two occasions one month apart and/or tissue eosinophilia
Hypereosinophilic syndrome (HES)	Blood HE and organ damage or dysfunction caused by tissue eosinophils
Familial (hereditary) hypereosinophilia	Frequently detected in childhood and sometimes associated with immunodeficiencies
Hypereosinophilia of unknown significance	Without familial clustering, underlying pathology, related molecular (genetic) abnormalities or hypereosinophilia-driven organ damage
Primary hypereosinophilia	Driven by clonal neoplastic eosinophils
Secondary (reactive) hypereosinophilia	Non-clonal eosinophilia driven by overproduced cytokines
Possible causes of secondary eosinophilia	Infections, parasites, allergy/atopy, hypersensitivity conditions, drug reactions, EGPA, ABPA, metabolic conditions, hematological conditions, EGID, rare diseases

Figure 2 - Diagnostic workup of persistent eosinophilia.

antibodies (ANCA) and imaging tests (chest x-ray, electrocardiogram and echocardiography, and CT scan of the chest, abdomen and pelvis) are suggested by the patient's travel history, presenting symptoms, and findings on physical examination. For eosinophilic lung diseases, pulmonary function testing, bronchoscopy, serologic tests (*e.g.*, *Aspergillus*-specific IgE for diagnosing ABPA) may be obtained to further characterize lung involvement. Endoscopy, gastrointestinal (GI) imaging and fecal calprotectin could be useful for GI symptoms, and at the same time an electromyograph to exclude peripheral neuropathy. The diagnostic workup we propose in case of persistent unexplained eosinophilia or hypereosinophilia is summarized in **figure 2**.

The spectrum of eosinophilic diseases: allergist's point of view

Eosinophils are involved in a wide array of homeostatic processes and pathological diseases. Through the growing understanding of eosinophil physiopathology, it will be possible to better understand the role of eosinophils in disease, and ultimately develop more effective precision therapies. Novel targeted biologics have not only had a major impact on treatment strategies, but also have resulted in major advances in our understanding of the pathogenesis of these disorders. Our increased understanding of type 2 inflammation and biology has recently led to development of highly effective targeted therapies that are now approved for several eosinophilic disorders (21).

Eosinophilic asthma and CRSwNP

Asthma is the most common chronic respiratory illness, affecting about 14% of children and 6% of adults globally with rising prevalence. Severe asthma (SA) affects up to 10% of asthmatic patients and represents a major economic issue worldwide (22). Asthma is characterized by reversible airflow obstruction, airway inflammation and bronchial hyperresponsiveness. Our

understanding of asthma as a heterogenous disease with different phenotypes and endotypes has evolved through improved understanding of biologic pathways leading to Type 2 high or Type 2 low inflammation. Over half of asthmatics have type 2 inflammation, characterized by release of IL-4, IL-5 and IL-13 from innate and adaptive immune cells and elevated fractional exhaled nitric oxide (FeNO), serum IgE or blood and sputum eosinophils (21, 23). Type 2 low asthma has been identified by several authors as asthma characterized by increased neutrophils in sputum and/or the absence of type 2 biomarkers. It is mediated by IL-1 β , IL-6, and IL-17 (21, 23). Eosinophils have long been recognized as an important element in asthmatic inflammation. This persistent airway inflammation is partly responsible for the high frequency of exacerbations seen in severe eosinophilic asthma. Early studies demonstrated the association of blood and tissue eosinophilia with bronchial asthma, and the relationship between elevated circulating eosinophil count and disease severity (24, 25). Furthermore, blood eosinophil count was identified as a treatable trait and was established as a validated pharmacodynamic and predictive biomarker for response to biologics like mepolizumab or benralizumab in patients with severe eosinophilic asthma (26). Biologics have had significant impact on patients with severe asthma, reducing symptoms and exacerbations, while improving lung function. The treatment decision of which biologic to use is driven by the clinical characteristics of patients and biomarkers even if phenotypes and endotypes often overlap with each other; all biologics have demonstrated variable effectiveness in type 2 inflammation, eosinophil/FeNO/IgE high presentations (27). The anti-IgE monoclonal antibody (omalizumab) is effective in patients with symptomatic allergic asthma who have elevated IgE or directed against perennial allergens (such as dust mites and molds), anti-IL-5/IL-5R agents are more effective in eosinophilic driven asthma.

Dupilumab has broader clinical indications and has been shown to be effective in patients with elevated eosinophils or FeNO; it has been approved for severe asthma patients, even those with oral glucocorticoid dependent asthma (28). Anti-Thymic Stromal Lymphopoietin (TSLP) therapy with tezepelumab, the most recently Food and Drug Administration (FDA) and European Medicines Agency (EMA) approved biologic, reduces asthma exacerbations and improved lung function in patients with blood eosinophils $> 300 \times 10^9/L$ and $< 300 \times 10^9/L$ compared to placebo, suggesting TSLP inhibition may have broader physiological effects, targeting high T2 and low T2 inflammatory pathways, independent of biomarker status (29). The effectiveness of biologic therapies is particularly evident, as observed after one year follow up from the Italian Registry on Severe Asthma (IRSA) in which the positive outcomes were found to be associated to certain factors such as baseline eosinophil count (30). CRSwNP is a chronic inflammatory disease of the nasal mucosa and sinuses that lasts at least 12 weeks with heterogeneous pathophysiology (31), and it is a frequent comorbidity in patients with severe eosinophilic asthma. It is characterized by type 2 inflammation with increased IL-4, IL-5, and IL-13 cytokines that lead to tissue infiltration with eosinophils, lymphocytes, basophils, and mast cells. The development of non-steroid antiinflammatory drugs (NSAIDs) exacerbated respiratory disease is often associated and may be mediated by a combination of factors including dysregulation of TSLP-immune response, mast cell activation by an innate type 2 response driven by cysteinyl leukotrienes, and IL-33 (32). IL-5 was implicated in the pathogenesis of nasal polyps (NP) in 1997 when it was found in significant amounts in the NP tissue samples from patients with asthma undergoing polypectomy (33). Neutralization of IL-5 led to a reduction in eosinophilia in the NP tissues (34). But the elimination of eosinophils doesn't improve the symptoms (35). Later, in 2010, IL-5 was found to significantly predict comorbid asthma in patients with NP (36). Clinical symptoms of CRSwNP are nasal blockage, loss of smell (anosmia), nasal discharge, facial pain/pressure, and sneezing because of nasal mucosal thickening and the formation of nasal polyps. Dupilumab was the first FDA and EMA approved biologic for treatment of CRSwNP, followed by omalizumab and mepolizumab (32). All showed improvement in symptoms and imaging and reduced exacerbations. Recent findings from Matucci *et al.* confirm the existence in humans of two phenotypic subsets of circulating and tissue resident eosinophils with differential surface expression of CD62L suggesting that the peripheral blood constitutes the likely source of tissue inflammatory eosinophils with pathogenic activity (37). This implicates that the count of circulating inflammatory eosinophils (iEos) could provide an insight into the inflammatory state of both pulmonary and nasal tissues and eventually become a new biomarker of type 2 inflammation, as IL-5 has been shown to cause CD62L downregulation or shed-

ding (38). Furthermore, circulating levels of iEos might represent a biomarker predictive of clinical response to an anti-IL-5 therapeutic strategy. Both blood eosinophils and iEos are predictive biomarker of efficacy of mepolizumab in severe eosinophil asthma, but both are not predictive biomarkers of efficacy of mepolizumab in concomitant CRSwNP (39). Eosinophilia and T2 inflammation require a comprehensive management approach involving allergists and other specialists from different medical disciplines.

Primary eosinophilic disorders of the gastrointestinal tract

Eosinophilic disorders of the gastrointestinal tract (EGID) are a heterogeneous group of diseases characterized by eosinophilic infiltration and organ dysfunction of the gut which occur in the absence of secondary causes, *i.e.*, drugs, parasitic infections, and vasculitis, such as eosinophilic granulomatosis of polyangiitis (EGPA) or primary hyper-eosinophilic syndromes (40). The interest in EGID has considerably risen in the last years due to the increased awareness of these diseases, the advances in the knowledge of their pathogenesis, and the possibility, for some of them, to treat them with biological therapies which are either approved, such as a monoclonal antibody targeting IL4 and IL13, dupilumab, for eosinophilic esophagitis (EoE) or being evaluated in clinical trials (40, 41). EGID are classified according to the main involved segment of the gastrointestinal tract and include eosinophilic esophagitis (EoE), eosinophilic gastritis, eosinophilic enteritis and eosinophilic colitis, targeting the esophagus, the stomach, the small, and the large bowel respectively (42). When the combined involvement of more than one segment is present, both should be stated separately. Moreover, according to recent nomenclature guidelines, especially with reference to small and large intestine, the precise layer of the gut involved if known, *i.e.*, the mucosa, the muscularis or the serosa, should be specified along with complications when present (42) (**table II**). Among these disorders, EoE is the most frequent and hence the more studied (42). On the other spectrum, eosinophilic colitis (EoC) is the rarest and less known condition among EGID, and its diagnostic histologic criteria pertaining the eosinophil cut-off level are still debated (43). Moreover, EoE is the only disease among EGID being associated with submucosal fibrosis, which is a Th-2 mediated phenomenon. If left untreated fibrosis leads to stenosis and small caliber-esophagus (44). Clinical manifestations vary according to the segment of the gut involved. In adults the major classifying symptom of EoE is troublesome dysphagia with solid foods, particularly meat, with food impaction often requiring endoscopic removal. In children, clinical manifestations of EoE are more heterogeneous and vary with age and include vomiting, regurgitation, abdominal pain dyspepsia, feeding failure to thrive in toddlers and young children, while dysphagia is present in adolescents (40). Eosinophilic gastritis presents with dyspepsia, heartburn, nausea/vomiting and

abdominal pain. Small and large bowel involvement usually is more frequently associated with diarrhea, abdominal pain and weight loss, but constipation and ascites are also described (45). A T helper (Th) 2 pathogenesis has been convincingly ascertained in both human studies and experimental for most cases of EoE, which has been recognized as the last step of progression of the most trajectories of atopic multimorbidity, after eczema, IgE-mediated food allergy, asthma and allergic rhinitis (46-48). The three key elements in the pathogenesis of EoE are epithelial barrier dysfunction, a prominent Th2 inflammatory process, and fibrosis (49). More precisely allergens (both aero and food ones), environmental factors such as pollutants, microbes, an acidic microenvironment are involved as triggers of the disease in predisposed patients, such as those with genetical alterations in epithelial barrier proteins (49). Eosinophils, which are prominent tissue damage mediators in EGID due to their granular proteins appears to be secondarily attracted in the submucosa by other cell types, such as Th2 cells, mast cells and innate lymphoid cells (50, 51). Diagnosis of EGID rests upon both endoscopy and histology. Moreover, they are essential to assess disease activity in response to treatment. Around 90% of patients with EoE present endoscopic abnormalities, including those reflecting inflammation, such as exudates, edema, furrows, mucosal fragility on the endoscope passage, and those reflecting fibrosis and remodeling, such as plaques, strictures, transient or fixed rings and a small-calliper esophagus. The prevalence of these alterations varies with age and disease duration (52). These endoscopic features have been incorporated in a validated grading system for EoE named EREFS, which stands for Exudates, Rings, Edema, Furrows, Stricture, which predicts with high accuracy the diagnosis of EoE in both adults and children (53). Despite its usefulness, endoscopy alone is not sufficient to make a diagnosis and assess disease activity, since in up to a quarter of patients, especially children, no endoscopic abnormalities are found (53). Endoscopic appearance of other EGID is variable and unspecific and include fold thickenings, mucosal erythema, polyps, ulcerations. However, in up to 50% endoscopic exams are normal (54). Besides, mucosal involvement may be absent in case of muscular and serosal disease. Given the patchy distribution of eosinophil infiltrates in EGID, several samples should be collected from different portions of the gut segment involved, usually at least two, and they should be focused on area characterized by mucosal endoscopic alterations (55). When no suggestive features are present at endoscopy, but clinical suspicion is high, biopsies should be randomly collected, in the case of the esophagus from all portions, upper, middle and lower third. Moreover, histological sampling should be performed after every therapeutical intervention, usually after 6 to 12 weeks, to assess response, since clinical manifestations alone are unreliable in predicting disease activity (55). The most important histological feature is the intraepithelial eosinophil infiltrate expressed as

the peak number of eosinophils counted in a high-power field (HPF). The diagnostic histological cut-off for eosinophil in the esophagus is 15/HPF and has a high accuracy in discriminating EoE from gastroesophageal reflux disease; it is also used to define histological remission (< 15 eosinophil/HPF) (55). Despite the marked tissue eosinophilia in the gut, serum eosinophilia in EGID is not always present and is usually not a prominent feature (40, 50). Therefore, these disorders should not be ruled out in the presence of normal eosinophil blood counts, and, on the contrary, in the setting of markedly increased eosinophil counts and gastrointestinal symptoms HES with secondary gut involvement should be considered instead. The natural history of EoE has been evaluated in observational studies and in the placebo arm of experimental studies and associated with chronic activity and relentless evolution to fibrosis in the absence of therapy (43). Hence a chronic treatment is generally recommended in EoE according to current guidelines (53, 55, 56). The clinical course of the other non-EoE EGID is still elusive. Indeed, their natural history appears to be more heterogenous, with different possible evolutions, such as persistent remission after one episode, a relapsing-remitting course or persistent activity after the first episode (57). The first line treatment modalities for EoE are protein pump inhibitors, topical swallowed steroids, and allergen-free diets (55, 56, 58, 59). More recently dupilumab have been approved by both the American and European drug regulatory agencies for the treatment of PPI refractory EoE in adults and adolescents aged 12 years or more and who weight more than 40 kilos, although its precise place in the management algorithm is yet to be determined (60-62). Allergen-free diets have a role in the treatment EoE and enable a drug-free treatment. According to Molina-Infante *et al.*, most patients with EoE display one or two food triggers, usually milk and wheat, hence currently food-elimination diets involve at first a reduced number of food categories, usually two, in the so-called two food elimination diet (FED) or 2-FED (63). This "bottom-up approach" is associated with less micro- and macro-nutrients deficiency and less demanding for the patient as compared to top-down approaches where more categories are eliminated from the beginning. If a clinic-histological response is not obtained after 8-12 weeks, more stringent elimination diets are instituted such as the 4-FED, in which four foods are eliminated including the previous two categories and egg and soy or six foods, including in addition shellfish and nuts (58, 59, 63). Allergy testing has not been found useful in predicting the food triggers in the single patients since they detect an IgE sensitization. However, when prescribing a diet, the concomitant food allergies of the patients should be considered, such as the frequent sensitization/allergy to lipid transfer protein (LTP) or legumes in the Mediterranean area which has been reported in same case series (59, 64). More precisely, sensitization/allergy to the peach LTP, Pru p 3, was reported as a frequent finding in the

Table II - Epidemiology, clinical and endoscopic features, diagnostic criteria, current therapeutic options in EGID.

	Eosinophilic esophagitis	Eosinophilic gastritis/enteritis	Eosinophilic colitis
Epidemiology (Prevalence)	0.5 to 1/1,000 individuals	6.3/100,000 and 8.4/100,000	3.3/100,000 individual
Diagnostic criteria (40, 50)	≥15 Eo/HPF from at least two sites (distal, mid or proximal esophagus)	≥30 Eo/HPF in ≥5 HPF or ≥70 Eo/HPF in ≥3 HPF (stomach) ≥52 Eo/HPF (duodenum) ≥56 Eo/HPF (ileum)	≥100 Eo/HPF (cecum/ascending colon) ≥84 Eo/HPF (transverse/descending colon) ≥ 64 Eo/HPF (sigma/rectum)
Clinical features	Vomiting, epigastric/chest pain, dysphagia, bolus impaction	-Mucosal form: vomiting, abdominal pain, diarrhea malabsorption, protein-losing enteropathy, iron-deficient anemia, failure to thrive (children), melena -Muscularis layer form [‡] : obstructive symptoms, such as dyspepsia -Serosal form [‡] : eosinophil-rich ascites	Abdominal pain, diarrhea, weight loss, anorexia
Endoscopic feature	-Linear oriented creases (furrowing) -Strictures -Mucosal rings -Whitish papules -Polyps	Micronodules	-Erythema [#] -Loss of vascularity [#] -Lymphonodular hyperplasia [#]
Histopathological features	Eosinophilic inflammation, eosinophil abscess, eosinophil surface layer, basal zone hyperplasia, dilated intercellular spaces, dyskeratotic epithelial cells, lamina propria fibrosis. Immunostaining for MCP, ECP, IgE, tryptase	Eosinophilic inflammation in different layers Blunt villi Immunostaining for MCP, ECP, IgE, tryptase	Eosinophil cryptitis/crypt abscesses, crypt architectural abnormalities, increased intraepithelial eosinophils, and eosinophils in muscularis mucosa and submucosa Immunostaining for MCP, ECP, IgE, tryptase
Laboratory parameters	Peripheral blood eosinophilia [‡]	Peripheral blood eosinophilia [‡]	Peripheral blood eosinophilia [‡]
Differential diagnoses	Infection HES Neoplasm CTD/SS Small vessel vasculitis Drug reaction	Infection HES Celiac Disease Crohn's disease CTD/SS Small vessel vasculitis Systemic mastocytosis Drug reaction	Infection HES Ulcerative colitis Crohn's disease CTD/SS Small vessel vasculitis Systemic mastocytosis Drug reaction
Association with allergic disorders [§]	+++	++	+
Predominant allergic phenotype	IgE T-cell	IgE T-cell	T-cell
Evolution	Esophageal stenosis if left untreated	Possible disease remission if pediatric onset	Benign course in infants
Therapeutic options	Elemental Diet, 6-, 4-, and 2- FED Topical glucocorticoid Dupilumab	Elemental diets Topical and systemic glucocorticoid	Elemental diet Topical and systemic glucocorticoid

CTD: connective tissue disease; HES: hypereosinophilic syndrome; HPF: high power field; FED: food elimination diet; SS: systemic sclerosis; [‡]it is not an universally present feature; [§]it denotes the strength of the evidence supporting the association and not its intensity; ^{*}it is given when only few studies are available; [‡]it tissue eosinophilia not usually detected; [#]it mainly present in rectum but possibly extending to the whole colon; with adaptations from Rossi CM, Lenti MV, Merli S, Licari A, Votto M, Marseglia GL, *et al.* Primary eosinophilic gastrointestinal disorders and allergy: Clinical and therapeutic implications. Clin Transl Allergy. 2022;12(5):e12146. doi: 10.1002/ctt2.12146.

study of EoE patients from Italy, being present in almost 50% of patients with EoE, and was also detected in patients with other primary eosinophilic disorders of the gastrointestinal tract. Most patients in this series were already avoiding peaches and other LTP-containing foods, for IgE-mediated manifestations ranging from contact urticaria to anaphylaxis (64). The sensitization/allergy to Pru p 3, a cross-reactive and thermal- and acidic-resistant allergen present in the peel or seeds of many fruits and vegetables, significantly complicates the management and quality of life of patients with EoE, because it may hence impose significant further dietary restrictions in EoE patients undergoing diet therapy, especially those on 4-FED or 6-FED. On the other hand, long term PPI therapy may expose EoE patients allergic to pathogenesis-related (PR)-10 allergens to systemic reactions. Topical steroids have an important role in EoE since they induce a clinical, histological, and endoscopic improvement. They exert a direct anti-inflammatory effect on the mucosa, promote mucosal integrity, decrease fibrogenic cytokines and hence possibly fibrosis. Induction therapy, ranges from 2 to 12 weeks. Maintenance therapy at the lowest dosage should be continued possibly indefinitely, given the high risk of relapse (65). While systemic steroids EoE are generally not recommended in EoE according to therapeutical guidelines (55, 56), they have a recognized role in the treatment of non-EoE EGID especially in the case of acute severe exacerbations (66). Moreover, a surgical approach may be warranted in case of obstruction especially when muscular involvement is present. Topical steroids are usually reserved for maintenance therapy together with immunosuppressants to prevent relapses. The role of allergen-free diets is currently recommended for eosinophilic gastritis, while its role in more distal eosinophilic disorders still needs to be ascertained (62). Actively screening atopic patients for EGID could be an effective strategy to reduce the diagnostic delay of this disorders and possibly improve clinical outcomes. Male patients with atopic comorbidity and any degree of dysphagia are the patients at risk for EoE and these parameters are already considered in a diagnostic algorithm which evaluates probability of having EoE before endoscopy (67). On the other spectrum, patients at risk for eosinophilic colitis are young female with atopic disorders presenting with diarrhea and elevation of fecal calprotectin when an endoscopy is not diagnostic for inflammatory bowel disease (68).

Eosinophilic granulomatosis with polyangiitis (EGPA)

Eosinophilic granulomatosis with polyangiitis (EGPA; formerly known as Churg-Strauss syndrome) is a rare small-vessel vasculitis that occurs in patients with asthma and eosinophilia and is histologically characterized by tissue eosinophilia, necrotizing vasculitis and eosinophil-rich granulomatous inflammation. The incidence of EGPA ranges between 0.5 and 4.2 cases per million people per year and its prevalence between 10 and 14

cases per million inhabitants globally. The frequency of the disease is comparable in men and women, and the mean age at diagnosis is ~50 years. Pediatric cases are extremely rare (69). The clinical phenotype of EGPA is quite heterogeneous and the diagnosis is not always straightforward. Anti-neutrophil cytoplasmic antibodies (ANCA), usually against myeloperoxidase (MPO), are detectable in ~40% of the cases and are associated with a different frequency of clinical manifestations: features of vasculitis, particularly glomerulonephritis, peripheral neuropathy and purpura, occur more often in ANCA-positive patients, whereas the so-called eosinophilic features such as cardiac involvement and gastroenteritis are more frequent in ANCA-negative patients (70, 71). Asthma and ear-nose-throat disease, which occur in > 90% and 60-80% of patients with EGPA, respectively, are equally distributed in the ANCA-positive and ANCA-negative groups. Histopathological evidence of vasculitis is more common in ANCA-positive than in ANCA-negative patients, although EGPA lesions usually include eosinophilic infiltrates along with necrotizing vasculitis and are therefore difficult to categorize as vasculitic or eosinophilic (72). Several cell types participate in the immunopathogenesis of the disease. Eosinophils are clearly central and are likely to mediate tissue damage, a concept supported by the evidence that targeting IL-5 (for example, using mepolizumab), a survival factor for eosinophils, is an effective therapy for EGPA (71, 72). CD4⁺ T cells orchestrate the adaptive immune response and are polarized towards a T helper 2 (TH2) phenotype, which enhances eosinophilic reactions; however, Th1 and Th17 cells might also have a role, especially in vasculitis and granuloma formation (73). EGPA has been classically described as a three-stages disease (73). The first stage is almost always present, with asthma being documented in about 100% of EGPA cases (70, 71, 74). The other two stages can often overlap. Alternatively, some patients may never experience the vasculitic phase, while others may directly develop vasculitis without any eosinophil-related organ damage in addition to respiratory tract involvement (73). Historically, conventional treatment was with oral corticosteroids (OCS), with or without additional immunosuppressive drugs, but many patients experienced corticosteroid-related side effects or relapses during OCS tapering. As a result, healthcare resource utilization and burden of disease and treatment were high (75). Since eosinophils contribute to the pathophysiology of EGPA, and with severe eosinophilic asthma being a key feature of the disease, mepolizumab was postulated as a potential treatment option for patients with EGPA. Following the promising early findings, which showed reductions in OCS and exacerbation rates with mepolizumab, recruitment of patients with relapsing or refractory EGPA (regardless of ANCA status) who were receiving standard of care therapy began in 2014 for the Phase III MIRRA (mepolizumab in relapsing or refractory EGPA; NCT02020889) trial (76). In this 136-patient study,

Table III - Clinical variants of HES.

Variants of HES	Features	Epidemiology
Myeloid HES	Intrinsic defect of eosinophilic committed neoplastic progenitor cells caused by mutations	10-20% of cases
Lymphocytic HES	Clonal T lymphocytes producing cytokines such as IL-3 and IL-5 that stimulate growth, differentiation and survival of eosinophils	10-20% of cases
Overlap HES	Overlapping forms with other conditions (EGPA, EGID, IgG4-related disease)	12-32% of cases
Associated HES	Due to secondary cause such as drug reaction, infection, neoplasm, immunologic disorders	10% of cases
Familial HES	Familial forms with autosomal dominant transmission	Rare
Idiopathic HES	HES who remain unexplained after ruling out parasitic, drug-induced, inflammatory and paraneoplastic causes as well as clonal and lymphocytic	35-50% of cases

add-on mepolizumab therapy (300 mg SC) *versus* placebo, led to a reduction in blood eosinophil count and more accrued time in remission, reduced the rate of relapse, and allowed patients to decrease their OCS use. Based on these findings, mepolizumab 300 mg SC was approved for EGPA in the USA in 2017 and in Europe soon after. However, a *post-hoc* analysis using a composite endpoint comprising remission, OCS reduction, and/or being relapse free for the treatment period showed that mepolizumab provided clinical benefit in up to 87% of patients with EGPA beyond the remission-based primary endpoints (77). Early evidence of efficacy for other anti-IL-5 treatment benralizumab has also been shown (78) in recent small studies (≤ 10 patients). Benralizumab appears to be an effective treatment for refractory asthma or ear-nose-throat manifestations in EGPA and allows GC-sparing in two retrospective real-life studies (79, 80). A Phase III trial of benralizumab in EGPA is currently underway. Overall, the clinical benefits associated with eosinophil reduction in patients with EGPA confirmed that eosinophils contribute to EGPA disease pathology and supported the use of mepolizumab in eosinophil-driven diseases beyond severe eosinophilic asthma (26, 69). For his effectiveness also in EGPA, mepolizumab was recently added as a therapeutic option in EGPA guidelines (69, 81).

Hypereosinophilic syndrome (HES)

Hypereosinophilic syndromes are defined by the presence of sustained blood ($> 1.5 \times 10^9$ cells/L) or tissue hypereosinophilia (HE) and presumed or proven eosinophil-mediated organ or tissue involvement (4, 82) (**table I**). HES is a rare disorder for which robust epidemiologic data are scarce. The diversity of the conditions that fall within the spectrum of HES makes it difficult to accurately capture the incidence and prevalence of HES and associated eosinophilic disorders. HES can be further subdivided into clinical variants (**table III**). Approximately 80% of myeloproliferative HES cases are caused by an interstitial deletion on chromosome 4, producing the FIP1L1-PDGFR α fusion

gene which generates a constitutively active tyrosine kinase that promotes abnormal eosinophil development and altered IL-5 signaling. Clinically, increased serum tryptase and vitamin B12 levels are found in myeloproliferative HES (4, 82). The clinical picture of HES is proteiform since all organs can potentially be affected. The pathogenesis of HES depends on the mechanism by which eosinophils are activated. Regardless of the subtype, HES commonly presents as a very burdensome disease, characterized by non-specific symptoms (fatigue, fever, weight loss, myalgia) and multi-organ impairment mostly involving skin, lungs, digestive tract and hear (83, 84). Main clinical manifestations of HES are resumed in **table IV**. Nowadays, given the current state of knowledge and available treatments, only clonal forms and severe cardiac involvement are truly life-threatening (85). Idiopathic HES is form of main interest for allergists and clinical immunologists. It is characterized by persistent unexplained hypereosinophilia with organ damage. After ruling out parasitic, drug-induced, inflammatory, and paraneoplastic causes as well as clonal and lymphocytic HES, around 3/4 of cases of HE/HES remain unexplained: these are referred to as idiopathic HES. This diagnosis of exclusion only requires very seldom bone marrow cytology, cytogenetic or molecular testing and the latter should be performed mainly in cases of suspected clonal HE or lymphoma (84, 85). In the last years, it is precisely mepolizumab that highlighted a possible role of T2 inflammation in idiopathic HES. Indeed, this drug, originally approved for severe T2-eosinophilic asthma, interestingly showed effectiveness also in idiopathic HES (86-88). In any cases, first line treatment for HES remains glucocorticoid therapy, in addition to treating underlying causes, if identifiable. Of the biologic therapies, mepolizumab is the best studied. A randomized, double-blind placebo-controlled phase III clinical trial showed FIP1L1-PDGFR α -negative HES patients treated with mepolizumab experienced significantly reduced flares compared to placebo leading to its approval by the FDA in 2020 and soon after by EMA (88). In a phase 2 clinical trial in patients with

Table IV - Clinical manifestations of HES.

Involvement	Clinical features
Cutaneous	Pruritus, eczema, urticaria, angioedema, bullae, ulceration of the limbs or mucous membranes, splinter haemorrhages, fasciitis, livedo, purpura.
Pulmonary	Asthma, bronchiolitis, bronchitis, bronchiectasis, interstitial lung disease.
Cardiac	Myocarditis, pericarditis, valvular disease, endomyocardial fibrosis, dilated cardiomyopathy, intracavitary thrombus, coronary artery vasospasm.
Neurological	Ischemic cerebrovascular disease (usually bilateral and of watershed distribution), peripheral neuropathy, myelitis
Digestive	Eosinophilic esophagitis, eosinophilic gastritis, eosinophilic enteritis and eosinophilic colitis, eosinophilic ascites, eosinophilic cholangitis.
Vascular	Arterial and/or venous thrombosis. Thromboangiitis obliterans-like vasculopathy or eosinophilic vasculitis.
Rheumatologic	Arthritis, tenosynovitis, myositis

PDGFRA-negative HES treatment with benralizumab showed reduction in the AEC during the study period, in addition to improvement in other clinical and hematologic responses compared to placebo (89). Phase III clinical trials involving benralizumab are currently underway (NCT04191304).

Discussion

The aim of this review is to highlight the state of the art regarding the knowledge of blood eosinophilia and the most important related diseases of interest, focusing particularly on those where significant advancements have been made in targeted therapy towards type 2 inflammation in recent years and to underline the important role of allergists and clinical immunologists in diagnosing and treating such pathologies. Despite peripheral eosinophilia not being the hallmark of EGID, we decided to consider them because these are emerging conditions linked to eosinophil disorders and type 2 inflammation. Primary EGID belong to the spectrum of T2 inflammation, and at the same time should be considered in the differential diagnosis of patients presenting with hypereosinophilia, especially in the setting of gastrointestinal symptoms and type 2 comorbidities. Their diagnosis of EGID is particularly challenging and may require a holistic approach integrating functional aspects from different organ systems (40, 45). More precisely, even though they are characterized by tissue eosinophilic infiltrates, peripheral eosinophilia is not generally a prominent feature and thus useful diagnostic biomarker and possibly outcome measure (50). So, a high degree of suspicion is mandatory when confronted with evocative clinical clusters, such as male sex, atopy and dysphagia for EoE (40, 43) and female sex, atopy, diarrhea/abdominal pain, elevation of fecal calprotectin for eosinophilic colitis (68). Yet, primary EGID should be distinguished from HES or EGPA with secondary gastrointestinal involvement, because the pathogenesis and hence

treatment approach is different (40, 68). Indeed, at least for some of EGID, particularly EoE, eosinophil-targeted treatments as a class, as opposed to HES and EGPA, have not been successful in clinical trials, due to the fact that the clinical endpoint has not been attained, whereas dupilumab has clearly demonstrated an objective clinical and functional improvement in addition to tissue depletion of eosinophils (47, 50). For other non-EoE EGID no biological therapy is yet approved but some are under evaluation in clinical trials, so at present the main pharmacological therapies remain systemic/topical steroids and other immunosuppressants, according to the phase of disease (40). Inizio Regarding the role of type 2 inflammation in asthma, CRSwNP, and EoE among EGID, it is very important and quite well defined. However, concerning EGPA and HES, despite eosinophils being the main actors, considering that these are rare diseases affecting multiple organs, the role of type 2 inflammation is still debated. EGPA has been classically described as a three-stages disease. The first stage, previously defined as “allergic”, is characterized by T2-eosinophilic asthma and chronic rhinosinusitis (CRS) which can last for several years before the development of systemic manifestations. In our opinion, the term allergic is not the proper definition, since only 30–40% of EGPA patients have evidence of IgE-mediated allergic sensitization to aeroallergens (90, 91). In this sense, “T2 rhinobronchial” could be a more appropriate definition for the first stage. In the second stage, hypereosinophilia becomes systemic and involves other organs in addition to the respiratory tract (for instance eosinophilic myocarditis and gastroenteritis). However, in this context eosinophilic gastroenteritis is the expression of another T2 epithelial dysregulated response to the exposome, like asthma, rather than the evolution of a systemic T2 inflammation originating from asthma and involving internal organs. The third and last stage of EGPA is represented by polyangiitis, that is a necrotizing vasculitis of medium/small vessels, leading to clinical man-

ifestations such as glomerulonephritis, purpura, neuropathy (73). In this context, differential diagnosis between idiopathic HES and EGPA could be very challenging (92, 93), since there is a great degree of overlapping between the two conditions, even more if both diseases are considered as T2 disorders originating from T2-eosinophilic asthma. For example, in front of a patient with asthma, CRS, myocarditis and hypereosinophilia, it could be very difficult to establish if the diagnosis is EGPA (second stage) or idiopathic HES that could be defined T2-driven HES, especially in case of negative ANCA-status. However, as the name says, evidence of polyangiitis (vasculitis) should be present to make a diagnosis of EGPA. This concept was pointed out by 2022 ACR classification criteria, which introduced the entry criterion of a defined diagnosis of medium/small vessels vasculitis (81). In clinical practice, a defined diagnosis of vasculitis can be obtained through the biopsy of the suspected vasculitis-involved organ, *e.g.*, skin with purpura or kidney in presence of increased creatinine/proteinuria/hematuria. In case of neuropathy, even if this manifestation is strongly suggestive for vasculitis of vasa nervorum, it is quite difficult to establish a defined diagnosis, since nerve biopsy is not feasible in most centers. Thus, applying ACR 2022 criteria, a defined diagnosis of vasculitis could be probably obtained only in those patients presenting in an overt vasculitic stage, with typical vasculitic manifestations susceptible to bioptic procedures. In this sense, a revised nomenclature for the second non-vasculitic stage of EGPA has been suggested by some authors, who proposed the definition of "hypereosinophilic asthma with systemic non-vasculitic manifestations" (94), while other authors even proposed to consider the second stage of EGPA as idiopathic HES (95). In this way, we could propose the definition of T2-driven HES, characterized by T2-eosinophilic asthma, hypereosinophilia, negative ANCA status and systemic manifestations without vasculitic sings. Regarding EGPA, interestingly, typical vasculitic manifestations (glomerulonephritis, purpura, neuropathy) are observed much more frequently in ANCA-positive patients, which represent 30-40% of all EGPA patients (73). This strong relationship between ANCA and vasculitic manifestations could be explained by a direct role of ANCA in the pathogenesis of vasculitis. In this sense, a dual-pathogenesis model of EGPA has been recently proposed. According to this model, EGPA would be the result of the coexistence of T2-eosinophilic inflammation, responsible for asthma, CRS, and eosinophil-related organ damage (*e.g.*, myocarditis, gastroenteritis), and ANCA-mediated inflammation, responsible for vasculitic manifestations such as purpura, glomerulonephritis, neuropathy (96). ANCA would act as functional autoantibodies (type IIb hypersensitivity, Gell&Coombs) which stimulate neutrophils to attack vascular endothelial wall, configuring a proper autoimmune vasculitis, even if without immune complexes (97). The lack of activity of immune-complexes formation by ANCA would be a reasonable explanation for the pauci-immune

pattern observed on direct immunofluorescence in EGPA and other ANCA-associated vasculitides, previously defined for this reason pauci-immune by the Chapel Hill consensus conference (98). These evidences may rise the question whether ANCA could be used as a biomarker of vasculitis for EGPA diagnosis, allowing to distinguish between T2-driven HES (only T2-eosinophilic inflammation) and EGPA (T2-eosinophilic inflammation plus autoimmune vasculitis). However, the verbatim application of eosinophils/ANCA dualism cannot always be translated into routine clinical practice, since clinical manifestations typical of vasculitis can be observed also in ANCA-negative patients, albeit much less frequently. An International Consensus reported poor sensitivity/specificity of ANCA in differentiating "vasculitic" from "eosinophilic" EGPA, stating that ANCA cannot guide treatment decision (99). Recent evidence suggested that therapy with monoclonal antibodies (mAbs) such as mepolizumab, benralizumab (anti-IL-5-R) and dupilumab (anti-IL4/IL-13R α), selectively targeting T2-eosinophilic inflammation, could better elucidate the role of ANCA in the pathogenesis of vasculitis in EGPA. Indeed, some Authors recently documented relapse or new onset of ANCA-positive EGPA in patients undergoing anti-T2 mAbs for EGPA or severe asthma, respectively, accompanied by re-increase/new finding of p-ANCA positivity (100-103). In patients undergoing anti-IL-5/IL-5-R mAbs, blood eosinophilia was mild ($< 1,000 \times 10^9/L$) or even within the normal range at the time of EGPA relapse/onset (100-103), so that it could be hypothesized that symptoms were due to raised ANCA. Anti-IL-5 mAb mepolizumab 300 mg is now approved for EGPA and idiopathic HES in USA and Europe. The efficacy of mepolizumab in both T2-eosinophilic asthma and idiopathic HES suggests a possible common IL-5-driven pathogenesis, raising the question whether IL-5 hyperexpression, as it happens in asthma, is a result of T2 inflammation also in idiopathic HES. In this sense, a continuum between the two conditions could be hypothesized, with T2-eosinophilic asthma representing the origin of a "T2-driven HES" (improperly considered idiopathic?) with involvement of other organs in addition to the lung. This hypothesis could be reasonable in those patients affected by mepolizumab-responsive idiopathic HES with documented asthma/respiratory involvement, the percentage of which ranges from 44 to 95% in clinical trials (88, 89, 104). Interestingly, Kuang *et al.* found that patients affected by idiopathic HES with pulmonary involvement were significantly more likely to respond to mepolizumab (104). The hypothesis of a T2-driven HES originating from T2-eosinophilic asthma could be even more reasonable in the context of EGPA, considered a special variant of reactive immune-mediated HES according to the latest classifications (4, 83, 84). In both HES and EGPA, disease course can vary. Some patients with HES experience recurrent flares, while others have persistent disease that requires constant treatment. On the other hand, most patients with EGPA experience exacerbations of up-

per and lower airway symptoms and/or recurrent hypereosinophilia during SCS tapering, despite successful induction of remission. HES and EGPA are both eosinophilic diseases with serious and systemic manifestations, but they present unique challenges in diagnosis and treatment. The expertise of Allergists and Clinical Immunologists is critical in identifying and managing these conditions, drawing on their understanding of the pathogenetic mechanisms underlying type 2 inflammation.

Conclusions

Type 2 (T2) inflammation represents the arm of the immune system originally deputed to the defense against parasites and helminths (105). T2 inflammation starts with the presentation of the antigen by dendritic cells (DCs) to T CD4⁺ helper lymphocytes, which differentiate into T CD4⁺ helper 2 (Th2) lymphocytes, with consequent production of T2 cytokines: interleukin-5 (IL-5), interleukin-4 (IL-4), interleukin-13 (IL-13). These cytokines stimulate recruitment of effector cells such as eosinophils, basophils, and mast cells, and IgE synthesis by B lymphocytes. Particularly, IL-5 is responsible for eosinophils' recruitment and activation. In predisposed subjects, a dysregulated T2 inflammation can develop in epithelial barriers (airways, intestine, skin) in response to various antigens other than parasites or helminths: allergens, microorganisms, pollutants. This dysregulated epithelial T2 response leads to diseases such as asthma, rhinitis/rhinosinusitis, eosinophilic gastrointestinal disorders (EGID), atopic dermatitis (105, 106). Allergens are not the only antigens able to trigger a dysregulated T2 inflammation, and IgE-mediated allergic sensitization can be present without clinical significance or even absent in the above-mentioned diseases. Thus, rather than allergic disorders, T2 disorders would be a more appropriate definition, including also non-allergic eosinophilic diseases such as eosinophilic asthma, chronic rhinosinusitis, EGID, EGPA and HES. According to the heterogeneity of eosinophilic disorders a multidisciplinary approach should be adopted. In the context of a multidisciplinary team, Allergists and Clinical Immunologists with a deep knowledge of T2 inflammation and T2 disorders can better refine the eosinophilia workup and make the most appropriate diagnosis. This is a very important skill since considering T2 inflammation could have important diagnostic and therapeutic implications.

Fundings

None.

Contributions

AMM, CMR, MAP: conceptualization. All authors: data curation, formal analysis, writing – original draft, writing – review & editing.

Conflict of interests

The authors declare that they have no conflict of interests.

References

1. Jackson DJ, Akuthota P, Roufousse F. Eosinophils and eosinophilic immune dysfunction in health and disease. *Eur Respir Rev.* 2022;31(163):210150. doi: 10.1183/16000617.0150-2021.
2. Kang N, Kim TB. Eosinophilic-Associated Disease Overlap: What Do We Know About It? *Allergy Asthma Immunol Res.* 2023;15(5):539-42. doi: 10.4168/air.2023.15.5.539.
3. Quirce S, Cosío BG, España A, Blanco R, Mullol J, Santander C, et al. Management of eosinophil-associated inflammatory diseases: the importance of a multidisciplinary approach. *Front Immunol* 2023;14:1192284. doi: 10.3389/fimmu.2023.1192284.
4. Valent P, Klion AD, Roufousse F, Simon D, Metzgeroth G, Leiferman KM, et al. Proposed refined diagnostic criteria and classification of eosinophil disorders and related syndromes. *Allergy.* 2023;78(1):47-59. doi: 10.1111/all.15544.
5. Valent P, Klion AD, Horny HP, Roufousse F, Gotlib J, Weller PF, et al. Contemporary consensus on criteria and classification of eosinophil disorders and related syndromes. *J Allergy Clin Immunol.* 2012;130(3):607-12.e9. doi: 10.1016/j.jaci.2012.02.019.
6. Khoury JD, Solary E, Abla O, Akkari Y, Alaggio R, Apperley JF, et al. The 5th edition of the World Health Organization classification of haematolymphoid tumours: myeloid and histiocytic/dendritic neoplasms. *Leukemia.* 2022;36(7):1703-19. doi: 10.1038/s41375-022-01613-1.
7. Simon D, Simon HU. Eosinophilic disorders. *J Allergy Clin Immunol.* 2007;119(6):1291-300; quiz 1301-2. doi: 10.1016/j.jaci.2007.02.010.
8. Gotlib J. World Health Organization-defined eosinophilic disorders: 2017 update on diagnosis, risk stratification, and management. *Am J Hematol.* 2017;92(11):1243-59. doi: 10.1002/ajh.24880.
9. Valent P, Gleich GJ, Reiter A, Roufousse F, Weller PF, Hellmann A, et al. Pathogenesis and classification of eosinophil disorders: a review of recent developments in the field. *Expert Rev Hematol.* 2012;5(2):157-76. doi: 10.1586/ehm.11.81.
10. Grayson PC, Ponte C, Suppiah R, Robson JC, Craven A, Judge A, et al. DCVAS Study Group. 2022 American College of Rheumatology/European Alliance of Associations for Rheumatology Classification Criteria for Eosinophilic Granulomatosis with Polyangiitis. *Arthritis Rheumatol.* 2022;74(3):386-92. doi: 10.1002/art.41982.
11. Jesenak M, Diamant Z, Simon D, Tufvesson E, Seys SF, Mukherjee M, et al. Eosinophils-from cradle to grave: An EAACI task force paper on new molecular insights and clinical functions of eosinophils and the clinical effects of targeted eosinophil depletion. *Allergy.* 2023;78(12):3077-102. doi: 10.1111/all.15884.
12. Pardanani A, Patnaik MM, Tefferi A. Eosinophilia: secondary, clonal and idiopathic. *Br J Haematol.* 2006;133(5):468-92. doi: 10.1111/j.1365-2141.2006.06038.x.
13. Ganeva M, Gancheva T, Lazarova R, Troeva J, Baldaranov I, Vasilev I, et al. Carbamazepine-induced drug reaction with eosinophilia and systemic symptoms (DRESS) syndrome: report of four cases and brief review. *Int J Dermatol.* 2008;47(8):853-60. doi: 10.1111/j.1365-4632.2008.03637.x.

14. Campos LE, Pereira LF. Pulmonary eosinophilia. *J Bras Pneumol.* 2009;35(6):561-73. English, Portuguese. doi: 10.1590/s1806-37132009000600010.
15. Méndez-Sánchez N, Chávez-Tapia NC, Vazquez-Elizondo G, Uribe M. Eosinophilic gastroenteritis: a review. *Dig Dis Sci.* 2007;52(11):2904-11. doi: 10.1007/s10620-005-9011-2.
16. Korkmaz C, Yıldırım R, Dinler M, Cansu DU. Coexistence of IgG4-related disease and ANCA-associated vasculitis: case report and review of the literature. *Rheumatol Int.* 2024;44(3):557-72. doi: 10.1007/s00296-023-05419-x.
17. Reiter A, Gotlib J. Myeloid neoplasms with eosinophilia. *Blood.* 2017;129(6):704-14. doi: 10.1182/blood-2016-10-695973.
18. Endo M, Usuki K, Kitazume K, Iwabe K, Okuyama Y, Urabe A. Hypereosinophilic syndrome in Hodgkin's disease with increased granulocyte-macrophage colony-stimulating factor. *Ann Hematol.* 1995;71(6):313-4. doi: 10.1007/BF01697986.
19. Wardlaw AJ, Barwell J, Hitchman C, Shrine N, Bennett N, Adewoye A, et al. Familial hypereosinophilia associated with eosinophilic gastrointestinal symptoms in individuals with a missense mutation in CKLF-like MARVEL transmembrane domain containing 3. *Clin Exp Allergy.* 2021;00:1-4. doi: 10.1111/cea.13957.
20. Wardlaw AJ, Wharin S, Aung H, Shaffu S, Siddiqui S. The causes of a peripheral blood eosinophilia in a secondary care setting. *Clin Exp Allergy.* 2021;51(7):902-14. doi: 10.1111/cea.13889.
21. Bernstein JS, Wechsler ME. Eosinophilic respiratory disorders and the impact of biologics. *Curr Opin Pulm Med.* 2023;29(3):202-8. doi: 10.1097/MCP.0000000000000951.
22. GBD Chronic Respiratory Disease Collaborators. Prevalence and attributable health burden of chronic respiratory diseases, 1990-2017: a systematic analysis for the Global Burden of Disease Study 2017. *Lancet Respir Med.* 2020;8(6):585-96. doi: 10.1016/S2213-2600(20)30105-3.
23. Hammad H, Lambrecht BN. The basic immunology of asthma. *Cell.* 2021;184(6):1469-85. doi: 10.1016/j.cell.2021.02.016.
24. Frigas E, Gleich GJ. The eosinophil and the pathophysiology of asthma. *J Allergy Clin Immunol.* 1986;77(4):527-37. doi: 10.1016/0091-6749(86)90341-6.
25. Bousquet J, Chanez P, Lacoste JY, Barnéon G, Ghavanian N, Enander I, et al. Eosinophilic inflammation in asthma. *N Engl J Med.* 1990;323(15):1033-9. doi: 10.1056/NEJM199010113231505.
26. Pavord ID, Bel EH, Bourdin A, Chan R, Han JK, Keene ON, et al. From DREAM to REALITI-A and beyond: Mepolizumab response in the treatment of eosinophil-driven diseases. *Allergy.* 2022;77(3):778-97. doi: 10.1111/all.15056.
27. Brusselle GG, Koppelman GH. Biologic Therapies for Severe Asthma. *N Engl J Med.* 2022;386(2):157-71. doi: 10.1056/NEJMra2032506.
28. Oppenheimer J, Hoyte FCL, Phipatanakul W, Silver J, Howarth P, Lugogo NL. Allergic and eosinophilic asthma in the era of biomarkers and biologics: similarities, differences and misconceptions. *Ann Allergy Asthma Immunol.* 2022;129(2):169-80. doi: 10.1016/j.anai.2022.02.021.
29. Menzies-Gow A, Corren J, Bourdin A, Chupp G, Israel E, Wechsler ME, et al. Tezepelumab in adults and adolescents with severe, uncontrolled asthma. *N Engl J Med.* 2021;384(19):1800-09. doi: 10.1056/NEJMoa2034975.
30. Bilò MB, Martini M, Antonicelli L, Aliani M, Carone M, Cecchi L, et al. IRSA Follow-up Study Group. Severe asthma: follow-up after one year from the Italian Registry on Severe Asthma (IRSA). *Eur Ann Allergy Clin Immunol.* 2023;55(5):199-211. doi: 10.23822/EurAnnACI.1764-1489.304.
31. Rank MA, Chu DK, Bognanni A, Oykman P, Bernstein JA, Ellis AK, et al. The Joint Task Force on Practice Parameters GRADE guidelines for the medical management of chronic rhinosinusitis with nasal polyposis. *J Allergy Clin Immunol.* 2023;151(2):386-98. doi: 10.1016/j.jaci.2022.10.026.
32. Laidlaw TM, Mullol J, Woessner KM, Amin N, Mannent LP. Chronic Rhinosinusitis with Nasal Polyps and Asthma. *J Allergy Clin Immunol Pract.* 2021;9(3):1133-41. doi: 10.1016/j.jaip.2020.09.063.
33. Simon HU, Yousefi S, Schranz C, Schapowal A, Bachert C, Blaser K. Direct demonstration of delayed eosinophil apoptosis as a mechanism causing tissue eosinophilia. *J Immunol.* 1997;158(8):3902-8.
34. Foster PS, Hogan SP, Ramsay AJ, Matthaei KI, Young IG. Interleukin 5 deficiency abolishes eosinophilia, airways hyperreactivity, and lung damage in a mouse asthma model. *J Exp Med.* 1996;183(1):195-201. doi: 10.1084/jem.183.1.195.
35. Laidlaw TM, Prussin C, Panettieri RA, Lee S, Ferguson BJ, Adapa ND, et al. Dexamipexole depletes blood and tissue eosinophils in nasal polyps with no change in polyp size. *Laryngoscope.* 2019;129(2):E61-6. doi: 10.1002/lary.27564.
36. Bachert C, Zhang N, Cavaliere C, Weiping W, Gevaert E, Krysko O. Biologics for chronic rhinosinusitis with nasal polyps. *J Allergy Clin Immunol.* 2020;145(3):725-39.
37. Matucci A, Nencini F, Maggiore G, Chiccoli F, Accinno M, Vivarelli E, et al. High proportion of inflammatory CD62L^{low} eosinophils in blood and nasal polyps of severe asthma patients. *Clin Exp Allergy.* 2023;53(1):78-87. doi: 10.1111/cea.14153.
38. Johansson MW. Activation states of blood eosinophils in asthma. *Clin Exp Allergy.* 2014;44(4):482-98. doi: 10.1111/cea.12292.
39. Lipworth B, Chan R, Misirovs R, Stewart K. Mepolizumab response in severe chronic rhinosinusitis with nasal polyps is dissociated from blood eosinophil levels. *J Allergy Clin Immunol.* 2022;149(5):1817. doi: 10.1016/j.jaci.2022.02.017.
40. Rossi CM, Lenti MV, Merli S, Licari A, Votto M, Marseglia GL, et al. Primary eosinophilic gastrointestinal disorders and allergy: Clinical and therapeutic implications. *Clin Transl Allergy.* 2022;12(5):e12146. doi: 10.1002/ct2.12146.
41. Peterson K, Safroneeva E, Schoepfer A. Emerging Therapies for Eosinophilic Gastrointestinal Diseases. *J Allergy Clin Immunol Pract.* 2021;9(9):3276-81. doi: 10.1016/j.jaip.2021.07.031.
42. Dellon ES, Gonsalves N, Abonia JP, Alexander JA, Arva NC, Atkins D, et al. International Consensus Recommendations for Eosinophilic Gastrointestinal Disease Nomenclature. *Clin Gastroenterol Hepatol.* 2022;20(11):2474-84.e3. doi: 10.1016/j.cgh.2022.02.017.
43. Dellon ES, Hirano I. Epidemiology and Natural History of Eosinophilic Esophagitis. *Gastroenterology.* 2018;154(2):319-32.e3. doi: 10.1053/j.gastro.2017.06.067.
44. Collins MH, Capocelli K, Yang GY. Eosinophilic Gastrointestinal Disorders Pathology. *Front Med (Lausanne).* 2018;4:26. doi: 10.3389/fmed.2017.00261.
45. Rothenberg ME. Eosinophilic gastrointestinal disorders (EGID). *J Allergy Clin Immunol.* 2004;113(1):11-28. doi: 10.1016/j.jaci.2003.10.047.
46. Hill DA, Grundmeier RW, Ramos M, Spergel JM. Eosinophilic Esophagitis Is a Late Manifestation of the Allergic March. *J Allergy Clin Immunol Pract.* 2018(5):1528-33. doi: 10.1016/j.jaip.2018.05.010.
47. Rothenberg ME, Dellon ES, Collins MH, Hirano I, Chehade M, Bredenoord AJ, et al. Efficacy and safety of dupilumab up to 52 weeks in adults and adolescents with eosinophilic oesophagitis (LIBERTY EoE TREET study): a multicentre, double-blind, ran-

- domised, placebo-controlled, phase 3 trial. *Lancet Gastroenterol Hepatol.* 2023;8(11):990-1004. doi: 10.1016/S2468-1253(23)00204-2.
48. Avlas S, Shani G, Rhone N, Itan M, Dolitzky A, Hazut I, et al. Epithelial cell-expressed type II IL-4 receptor mediates eosinophilic esophagitis. *Allergy.* 2023;78(2):464-76. doi: 10.1111/all.15510.
 49. Simon D, Cianferoni A, Spergel JM, Aceves S, Holbreich M, Venter C, et al. Eosinophilic esophagitis is characterized by a non-IgE-mediated food hypersensitivity. *Allergy.* 2016;71:611-20. doi: 10.1136/gutjnl-2023-329864.
 50. Rossi CM, Lenti MV, Di Sabatino A. Toning down the role of eosinophils in eosinophilic oesophagitis. *Gut.* 2024;73(5):874-5. doi: 10.1136/gutjnl-2023-329864.
 51. Dellon ES, Chen X, Miller CR, Fritchie KJ, Rubinas TC, Woosley JT, Shaheen NJ. Tryptase staining of mast cells may differentiate eosinophilic esophagitis from gastroesophageal reflux disease. *Am J Gastroenterol.* 2011;106(2):264-71. doi: 10.1038/ajg.2010.412.
 52. Visaggi P, Savarino E, Sciume G, Chio TD, Bronzini F, et al. Eosinophilic esophagitis: clinical, endoscopic, histologic and therapeutic differences and similarities between children and adults. *Therap Adv Gastroenterol.* 2021;14:1756284820980860. doi: 10.1177/1756284820980860.
 53. Dellon ES, Liacouras CA. Advances in clinical management of eosinophilic esophagitis. *Gastroenterology.* 2014;147(6):1238-54. doi: 10.1053/j.gastro.2014.07.055.
 54. Zhang M, Li Y. Eosinophilic gastroenteritis: A state-of-the-art review. *J Gastroenterol Hepatol.* 2017;32(1):64-72. doi: 10.1111/jgh.13463.
 55. Lucendo AJ, Molina-Infante J, Arias Á, von Arnim U, Bredenoord AJ, Bussmann C, et al. Guidelines on eosinophilic esophagitis: evidence-based statements and recommendations for diagnosis and management in children and adults. *United European Gastroenterol J.* 2017;5(3):335-58. doi: 10.1177/2050640616689525.
 56. Dhar A, Haboubi HN, Attwood SE, Auth MKH, Dunn JM, Sweis R, et al. British Society of Gastroenterology (BSG) and British Society of Paediatric Gastroenterology, Hepatology and Nutrition (BSPGHAN) joint consensus guidelines on the diagnosis and management of eosinophilic oesophagitis in children and adults. *Gut.* 2022;71(8):1459-87. doi: 10.1136/gutjnl-2022-327326.
 57. Pineton de Chambrun G, Gonzalez F, Canva JY, Gonzalez S, Houssin L, Desreumaux P, et al. Natural history of eosinophilic gastroenteritis. *Clin Gastroenterol Hepatol.* 2011;9(11):950-6.e1. doi: 10.1016/j.cgh.2011.07.017.
 58. Votto M, De Filippo M, Lenti MV, Rossi CM, Di Sabatino A, Marsaglia GL, Licari A. Diet Therapy in Eosinophilic Esophagitis. Focus on a Personalized Approach. *Front Pediatr.* 2022;9:820192. doi: 10.3389/fped.2021.820192.
 59. Rossi CM, Lenti MV, Merli S, Cena H, Di Sabatino A. Dietary Strategies in Adult Patients with Eosinophilic Esophagitis: A State-of-the-Art Review. *Nutrients.* 2023;15(10):2409. doi: 10.3390/nu15102409.
 60. Al-Horani RA, Chiles R. First Therapeutic Approval for Eosinophilic Esophagitis. *Gastroenterol Insights.* 2022;13(3):238-44. doi: 10.3390/gastroent13030024.
 61. European Medicines Agency. Dupixent. Available at: <https://www.ema.europa.eu/en/medicines/human/EPAR/dupixent>.
 62. Aceves SS, Dellon ES, Greenhawt M, Hirano I, Liacouras CA, Spergel JM. Clinical guidance for the use of dupilumab in eosinophilic esophagitis: A yardstick. *Ann Allergy Asthma Immunol.* 2023;130(3):371-8. doi: 10.1016/j.anai.2022.12.014.
 63. Molina-Infante J, Lucendo AJ. Letter: dietary therapy in eosinophilic oesophagitis - do not test, just eliminate and reintroduce the most common food triggers. *Aliment Pharmacol Ther.* 2016;44(8):904-5. doi: 10.1111/apt.13742.
 64. Rossi CM, Lenti MV, Achilli G, Merli S, Mauro A, Anderloni A, et al. High prevalence of sensitization to non-specific lipid transfer protein in adult patients with primary eosinophilic gastrointestinal disorders in Italy: a single center series. *Clin Mol Allergy.* 2022;20(1):8. doi: 10.1186/s12948-022-00174-z.
 65. Reddy A, Ashat D, Murali AR. Recent insights on the use of topical steroids in eosinophilic esophagitis. *Expert Rev Gastroenterol Hepatol.* 2020;14(10):953-63. doi: 10.1080/17474124.2020.1785869.
 66. Walker MM, Potter M, Talley NJ. Eosinophilic gastroenteritis and other eosinophilic gut diseases distal to the oesophagus. *Lancet Gastroenterol Hepatol.* 2018;3:271-80. doi: 10.1016/S2468-1253(18)30005-0.
 67. Cotton CC, Betancourt R, Randall C, Perjar I, Bookhout C, Woosley JT, et al. A Model Using Clinical and Endoscopic Characteristics Identifies Patients at Risk for Eosinophilic Esophagitis According to Updated Diagnostic Guidelines. *Clin Gastroenterol Hepatol.* 2021;19(9):1824-34.e2. doi: 10.1016/j.cgh.2020.06.068.
 68. Rossi CM, Lenti MV, Merli S, Lo Bello A, Mauro A, Anderloni A, et al. Clinical and atopic features of patients with primary eosinophilic colitis: an Italian multicentre study. *Intern Emerg Med.* 2024;19(4):993-1005. doi: 10.1007/s11739-024-03568-w.
 69. Emmi G, Bettiol A, Gelain E, Bajema IM, Berti A, Burns S, et al. Evidence-Based Guideline for the diagnosis and management of eosinophilic granulomatosis with polyangiitis. *Nat Rev Rheumatol.* 2023;19(6):378-93. doi: 10.1038/s41584-023-00958-w.
 70. Comarmond C, Pagnoux C, Khellaf M, Cordier JF, Hamidou M, Villard JF, et al. Eosinophilic granulomatosis with polyangiitis (Churg-Strauss): clinical characteristics and long-term followup of the 383 patients enrolled in the French Vasculitis Study Group cohort. *Arthritis Rheum.* 2013;65(1):270-81. doi: 10.1002/art.37721.
 71. Sinico RA, Di Toma L, Maggiore U, Bottero P, Radice A, Tosoni C, et al. Prevalence and clinical significance of antineutrophil cytoplasmic antibodies in Churg-Strauss syndrome. *Arthritis Rheum.* 2005;52(9):2926-35. doi: 10.1002/art.21250.
 72. Mahr A, Moosig F, Neumann T, Szczeklik W, Taillé C, Vaglio A, Zwerina J. Eosinophilic granulomatosis with polyangiitis (Churg-Strauss): evolutions in classification, etiopathogenesis, assessment and management. *Curr Opin Rheumatol.* 2014;26(1):16-23. doi: 10.1097/BOR.000000000000015.
 73. Vaglio A, Buzio C, Zwerina J. Eosinophilic granulomatosis with polyangiitis (Churg-Strauss): state of the art. *Allergy.* 2013;68(3):261-73. doi: 10.1111/all.12088.
 74. Healy B, Bibby S, Steele R, Weatherall M, Nelson H, Beasley R. Anti-neutrophil cytoplasmic autoantibodies and myeloperoxidase autoantibodies in clinical expression of Churg-Strauss syndrome. *J Allergy Clin Immunol.* 2013;131(2):571-6.e1-6. doi: 10.1016/j.jaci.2012.05.058.
 75. Marvisi C, Sinico RA, Salvarani C, Jayne D, Prisco D, Terrier B, et al. New perspectives in eosinophilic granulomatosis with polyangiitis (EGPA): report of the first meeting of the European EGPA Study Group. *Intern Emerg Med.* 2019;14(8):1193-97. doi: 10.1007/s11739-019-02166-5.
 76. Wechsler ME, Akuthota P, Jayne D, Khoury P, Klion A, Langford CA, et al. Mepolizumab or Placebo for Eosinophilic Granulomatosis with Polyangiitis. *N Engl J Med.* 2017;376(20):1921-32. doi: 10.1056/NEJMoa1702079.
 77. Steinfeld J, Bradford ES, Brown J, Mallett S, Yancey SW, Akuthota P, et al. Evaluation of clinical benefit from treatment with mepolizumab for patients with eosinophilic granulomatosis with polyangiitis. *J Allergy Clin Immunol.* 2019;143(6):2170-7. doi: 10.1016/j.jaci.2018.11.041.
 78. Guntur VP, Manka LA, Denson JL, Dunn RM, Dollin YT, et al. Benralizumab as a Steroid-Sparing Treatment Option in Eosinophil-

- ic Granulomatosis with Polyangiitis. *J Allergy Clin Immunol Pract.* 2021;9(3):1186-93.e1. doi: 10.1016/j.jaip.2020.09.054.
79. Cottu A, Groh M, Desaintjean C, Marchand-Adam S, Guillevin L, Puechal X, et al. Benralizumab for eosinophilic granulomatosis with polyangiitis. *Ann Rheum Dis.* 2023;82(12):1580-6. doi: 10.1136/ard-2023-224624.
 80. Nanzer AM, Maynard-Paquette AC, Alam V, Green L, Thomson L, Lam J, et al. Long-term Effectiveness of Benralizumab in Eosinophilic Granulomatosis with Polyangiitis. *J Allergy Clin Immunol Pract.* 2024:S2213-2198(24)00017-5. doi: 10.1016/j.jaip.2024.01.006.
 81. Grayson PC, Ponte C, Suppiah R, Robson JC, Craven A, Judge A, et al. American College of Rheumatology/European Alliance of Associations for Rheumatology Classification Criteria for Eosinophilic Granulomatosis with Polyangiitis. *Ann Rheum Dis.* 2022;81(3):309-14. doi: 10.1136/annrheumdis-2021-221794.
 82. Shomali W, Gotlib J. World Health Organization-defined eosinophilic disorders: 2019 update on diagnosis, risk stratification, and management. *Am J Hematol.* 2019;94:1149-67.
 83. Klion AD, Ackerman SJ, Bochner BS. Contributions of Eosinophils to Human Health and Disease. *Annu Rev Pathol.* 2020;15:179-209. doi: 10.1146/annurev-pathmechdis-012419-032756.
 84. Groh M, Rohmer J, Etienne N, Abou Chahla W, Baudet A, Chan Hew Wai A, et al. French guidelines for the etiological workup of eosinophilia and the management of hypereosinophilic syndromes. *Orphanet J Rare Dis.* 2023;18(1):100. doi: 10.1186/s13023-023-02696-4.
 85. Podjasek JC, Butterfield JH. Mortality in hypereosinophilic syndrome: 19 years of experience at Mayo Clinic with a review of the literature. *Leuk Res.* 2013;37(4):392-5. doi: 10.1016/j.leukres.2012.12.016.
 86. Garrett JK, Jameson SC, Thomson B, Collins MH, Wagoner LE, Freese DK, et al. Anti-interleukin-5 (mepolizumab) therapy for hypereosinophilic syndromes. *J Allergy Clin Immunol.* 2004;113(1):115-9. doi: 10.1016/j.jaci.2003.10.049.
 87. Rothenberg ME, Klion AD, Roufosse FE, Kahn JE, Weller PF, Simon HU, et al. Treatment of patients with the hypereosinophilic syndrome with mepolizumab. *N Engl J Med.* 2008;358(12):1215-28. doi: 10.1056/NEJMoa070812.
 88. Roufosse F, Kahn JE, Rothenberg ME, Wardlaw AJ, Klion AD, Kirby SY, et al. Efficacy and safety of mepolizumab in hypereosinophilic syndrome: A phase III, randomized, placebo-controlled trial. *J Allergy Clin Immunol.* 2020;146(6):1397-405. doi: 10.1016/j.jaci.2020.08.037.
 89. Kuang FL, Legrand F, Makiya M, Ware J, Wetzler L, Brown T, et al. Benralizumab for PDGFRA-negative hypereosinophilic syndrome. *N Engl J Med.* 2019;380(14):1336-46. doi: 10.1056/NEJMoa1812185.
 90. Bottero P, Bonini M, Vecchio F, Grittini A, Patrino GM, Colombo B, Sinico RA. The common allergens in the Churg-Strauss syndrome. *Allergy.* 2007;62(11):1288-94. doi: 10.1111/j.1398-9995.2007.01486.x.
 91. Bello F, Maritati F, Radice A, Sinico RA, Emmi G, Vaglio A. Microarray evaluation of allergen-specific IgE in eosinophilic granulomatosis with polyangiitis. *Ann Rheum Dis.* 2021;80(9):1247-8. doi: 10.1136/annrheumdis-2021-220111.
 92. Khoury P, Akuthota P, Kwon N, Steinfeld J, Roufosse F. HES and EGPA: Two Sides of the Same Coin. *Mayo Clin Proc.* 2023;98(7):1054-70. doi: 10.1016/j.mayocp.2023.02.013.
 93. Wechsler ME, Hellmich B, Cid MC, Jayne D, Tian X, Baylis L, Roufosse F. Unmet needs and evidence gaps in hypereosinophilic syndrome and eosinophilic granulomatosis with polyangiitis. *J Allergy Clin Immunol.* 2023;151(6):1415-28. doi: 10.1016/j.jaci.2023.03.011.
 94. Cottin V, Bel E, Bottero P, Dalhoff K, Humbert M, Lazor R, et al. Revisiting the systemic vasculitis in eosinophilic granulomatosis with polyangiitis (Churg-Strauss): A study of 157 patients by the Groupe d'Etudes et de Recherche sur les Maladies Orphelines Pulmonaires and the European Respiratory Society Taskforce on eosinophilic granulomatosis with polyangiitis (Churg-Strauss). *Autoimmun Rev.* 2017;16(1):1-9. doi: 10.1016/j.autrev.2016.09.018.
 95. Lefèvre G, Ackermann F, Kahn JE. Hypereosinophilia with asthma and systemic (non-vasculitic) manifestations: Eosinophilic granulomatosis with polyangiitis or hypereosinophilic syndrome? *Autoimmun Rev.* 2017;16(2):208-9. doi: 10.1016/j.autrev.2016.11.001.
 96. Furuta S, Iwamoto T, Nakajima H. Update on eosinophilic granulomatosis with polyangiitis. *Allergol Int.* 2019;68(4):430-6. doi: 10.1016/j.alit.2019.06.004.
 97. Fagni F, Bello F, Emmi G. Eosinophilic Granulomatosis With Polyangiitis: Dissecting the Pathophysiology. *Front Med (Lausanne).* 2021;8:627776. doi: 10.3389/fmed.2021.627776.
 98. Jennette JC, Falk RJ, Bacon PA, Basu N, Cid MC, Ferrario F, et al. 2012 revised International Chapel Hill Consensus Conference Nomenclature of Vasculitides. *Arthritis Rheum.* 2013;65(1):1-11. doi: 10.1002/art.37715.
 99. Moiseev S, Bossuyt X, Arimura Y, Blockmans D, Csernok E, Damoiseaux J, et al. European EGPA Study Group. International Consensus on ANCA Testing in Eosinophilic Granulomatosis with Polyangiitis. *Am J Respir Crit Care Med.* 2020. doi: 10.1164/rccm.202005-1628SO. Epub ahead of print.
 100. Piga MA, Fraticelli P, Antonicelli L, Garritani MS, Ghirelli G, Martini M, et al. ANCA-negative EGPA: only eosinophils without vasculitis? Insights from anti-T2 biologics. *Front Immunol.* 2023;14:1325299. doi: 10.3389/fimmu.2023.1325299.
 101. Lim AKH, Antony A, Gingold M, Simpson I, Looi WF, MacDonald MI. Emergence of extrathoracic manifestations of eosinophilic granulomatosis with polyangiitis during benralizumab treatment. *Rheumatol Adv Pract.* 2021;5(2):rkab033. doi: 10.1093/rap/rkab033.
 102. Caminati M, Maule M, Nalin F, Senna G, Lunardi C. Onset of eosinophilic granulomatosis with polyangiitis in a patient treated with an IL-5 pathway inhibitor for severe asthma. *Rheumatology (Oxford).* 2021;60(2):e59-60. doi: 10.1093/rheumatology/keaa572.
 103. Suzaki I, Tanaka A, Yanai R, Maruyama Y, Kamimura S, Hirano K, Kobayashi H. Eosinophilic granulomatosis with polyangiitis developed after dupilumab administration in patients with eosinophilic chronic rhinosinusitis and asthma: a case report. *BMC Pulm Med.* 2023;23(1):130. doi: 10.1186/s12890-023-02415-6.
 104. Kuang FL, Fay MP, Ware J, Wetzler L, Holland-Thomas N, Brown T, et al. Long-Term Clinical Outcomes of High-Dose Mepolizumab Treatment for Hypereosinophilic Syndrome. *J Allergy Clin Immunol Pract.* 2018;6(5):1518-27.e5. doi: 10.1016/j.jaip.2018.04.033.
 105. Annunziato F, Romagnani C, Romagnani S. The 3 major types of innate and adaptive cell-mediated effector immunity. *J Allergy Clin Immunol.* 2015;135(3):626-35. doi: 10.1016/j.jaci.2014.11.001.
 106. Jutel M, Agache I, Zemelka-Wiacek M, Akdis M, Chivato T, Del Giacco S, et al. Nomenclature of allergic diseases and hypersensitivity reactions: Adapted to modern needs: An EAACI position paper. *Allergy.* 2023;78(11):2851-74. doi: 10.1111/all.15889.