

Figure 2A: Clinical features of HSR in the DPT (n=7) and RSA (n=2) of the 9 patients.

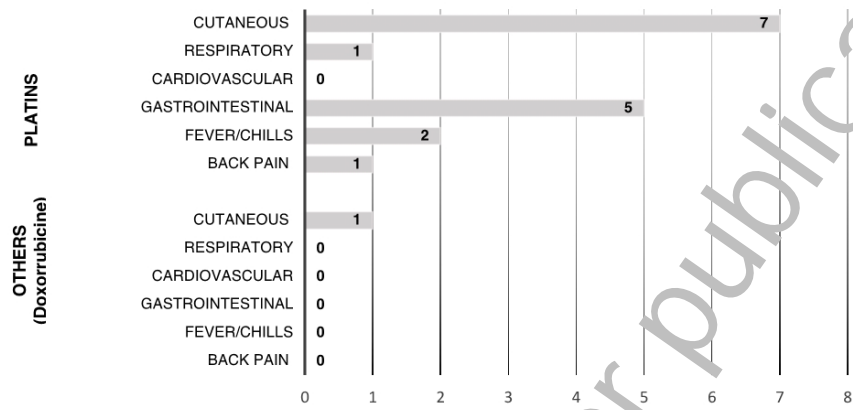


Figure 2B: Severity of HSRs in the DPT and RSA according to BG and RCUH classification.

