

A.T. AKENROYE<sup>1,2</sup>, N. MADAN<sup>1,2</sup>, F. MOHAMMADI<sup>3,4</sup>, J. LEIDER<sup>1,2</sup>

# Hemophagocytic Lymphohistiocytosis mimics many common conditions: case series and review of literature

<sup>1</sup>Department of Medicine, Jacobi Medical Center, Albert Einstein College of Medicine, 1400 Pelham Parkway S, Bronx, New York 10461, USA

<sup>2</sup>Department of Medicine, Albert Einstein College of Medicine, 1300 Morris Park Avenue, Bronx, New York 10461, USA

<sup>3</sup>Department of Pathology, Bellevue Hospital, 462 1st Ave, New York 10016, USA

<sup>4</sup>Department of Anatomic Pathology, New York University, 550 First Avenue, New York City, USA

## KEY WORDS

*Hemophagocytosis; hemophagocytic lymphohistiocytosis; macrophage activation syndrome; systemic inflammatory response syndrome; T-cell dysregulation; immune regulation*

## Corresponding author:

Ayobami Akenroye  
Department of Medicine,  
Jacobi Medical Center  
Building 1, 3N21, 1400 Morris Park  
Avenue Bronx, NY 10461, USA  
Phone: 718 918 7768  
Fax: 718 918 7460  
E-mail: ayobami.akenroye@post.harvard.edu

## Summary

**Introduction.** Hemophagocytic lymphohistiocytosis (HLH), a rare but potentially fatal disease, is characterized by excessive immune activation and cytokine release which stimulates bone marrow macrophages to engulf hematopoietic cells. HLH could be secondary to infections: viral, fungal, and bacterial; malignancies and autoimmune diseases. The diagnosis of HLH is usually delayed due to the presence of non-specific symptoms at presentation. This delay contributes to increased mortality. **Cases and review.** We present the case of 4 patients who presented with subjective fevers and extreme fatigue. Patients all had systemic inflammatory response syndrome (SIRS). All patients were initially managed as in sepsis from an underlying infection. All unfortunately progressed to multiple organs dysfunction and died. The underlying causes for HLH in the patients were considered to be: HIV/AIDS, T cell lymphoma, histoplasmosis and juvenile rheumatoid arthritis. We have also included a brief review of the literature on HLH highlighting the treatment and outcomes of patients in case series; and the many conditions which can trigger HLH. **Conclusion.** Patients with HLH usually share various non-specific symptoms, such as fever and malaise, with patients across a wide spectrum of conditions: from bacterial sepsis to malignancies. Since early suspicion and diagnosis is critical to prompt therapy and improved mortality, including HLH as a possible cause of fever particularly in patients with prolonged fever of unknown origin and cytopenias will be crucial.

## Introduction

Hemophagocytic lymphohistiocytosis (HLH), a rare but potentially fatal disease, is characterized by persistent immune activation and cytokine release which stimulates bone marrow (BM) macrophages to engulf hematopoietic cells. Over the past three decades there has been extensive research into the causes of HLH, its diagnosis, and its optimal management. This, in addition to the publication of the HLH-1994 and HLH-2004 diagnostic criteria and treatment protocols has led to an improvement in the prognosis of HLH (1). Since the publication

of the HLH-94 protocol, mortality in primary HLH has been shown to improve from about 100% in a few months to about 50% over a median follow-up of six years (2). However, the prognosis of secondary HLH, which is more common in adults, remains grave (3).

HLH could be primary or secondary (1,4). Primary or familial hemophagocytic lymphohistiocytosis (FHL) has underlying genetic mutations inherited in either an autosomal recessive pattern (perforin [PRF1], MUNC13-4, syntaxin 11 [STX11], STXBP2, and RAB27A genes) or X-linked pattern (SH2D1A

and XIAP/BIRC4 genes) (5-13). Secondary HLH (sHLH) has been described in patients with HIV/AIDS, malignancies such as lymphomas, viral infections, and mycobacterial infections. Autoimmune disorders, such as systemic lupus erythematosus, multiple sclerosis and myasthenia gravis, could also trigger HLH in which case it is usually referred to as macrophage activation syndrome (14). Although adults usually have sHLH, 10-15% of adults with HLH have an underlying genetic mutation, commonly in the perforin gene (15).

Herein, we report the clinical course of four adult patients who were diagnosed as having HLH in our center with emphasis on the similarities between their clinical presentations and features to facilitate increased suspicion and prompt diagnosis. Finally, we include a concise review of literature emphasizing common conditions associated with sHLH and outcomes of the patients reported.

## Methods

**Case Series:** We present briefly a summary of the clinical course of four adult patients.

**Review of the Literature:** Using the search terms “lymphohistiocytosis,” “hemophagocytosis,” “HLH,” “MAS,” alone and in all combinations, we identified reports of HLH in PubMed from 2004 through March 2015. We excluded case reports of single patients and included only case series of adult patients.

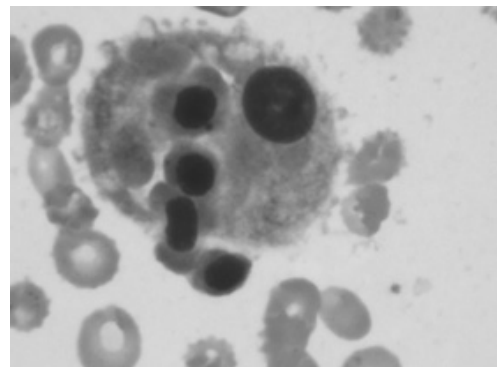
## Case series

All four patients (**table 1**), aged 20-60 yrs, initially presented with subjective fevers and extreme fatigue. 3 of the 4 were otherwise healthy patients with no significant comorbidity prior to current illness. Patient 1 had underlying HIV on highly active antiretroviral therapy (most recent CD4: 218, viral load < 20 copies/ml). On presentation, 3 of these 4 patients met SIRS criteria, most commonly being febrile and tachycardic and/or hypotensive. All were anemic and thrombocytopenic. Patient 1 was also leukopenic. All of these patients were initially treated with broad-spectrum empiric antibiotics for presumed sepsis although multiple bacterial cultures subsequently returned negative in all of them except in Patient 3, who later went on to develop *Enterobacter aerogenes* bacteremia weeks after the diagnosis of HLH. Due to persistent fevers, despite antibacterial regimen, and chronicity of symptoms, other etiology such as HIV/AIDS and tuberculosis were explored with an extensive workup for atypical bacteria, viruses, fungi and parasites given the hospital's location in an area with high incidence of HIV and large immigrant population. Ferritin levels were subsequently checked which was remarkably greater than 1000 ng/ml in all patients, and in Patients 1 and 4 peaked at 55,269 and 87,708 ng/ml respectively. Elevated ferritin and worsening cytopenias triggered bone marrow aspiration that led to the diagnosis of HLH. 3 of the 4 had hemophagocytes in

the bone marrow but all met criteria for HLH as defined in the HLH-2004 guidelines. The underlying disease potentially causing HLH was later considered to be HIV/AIDS in Patient 1, hepatosplenic T-cell lymphoma in Patient 2, and histoplasmosis in Patient 3. In Patient 4, who was 20 years old at time of diagnosis, the underlying etiology was considered to be juvenile rheumatoid arthritis. A few months after Patient 4 died, however, brother presented with similar illness. Genetic testing was however not pursued as per family's wishes.

Patients 1 and 2 both received 1 cycle of chemotherapy. Patients 3 and 4 were considered too sick at the time of HLH diagnosis with the risk of chemotherapy outweighing the perceived benefit. Patient 1, who was HIV-positive, initially showed improvement in clinical status and ferritin level dropped significantly by 75% while platelet count and leucopenia improved within the first 2 weeks of treatment. Patient however defaulted and was readmitted about 3 months after HLH diagnosis with herpes encephalitis. HLH relapsed and patient progressed to multi-organ failure (MODS) within 4 months of diagnosis. Patient 2 however continued to deteriorate despite chemotherapy. He progressed to multi-organ failure within 8 weeks of diagnosis. Patient 3 was initially placed on empirical anti-tuberculous regimen due to immigration from a tuberculosis-endemic area, and the presence of hilar lymphadenopathy and apical nodules on chest radiography. Repeated acid-fast bacilli stain of bronchial washings and mycology cultures of bone marrow biopsy specimen were however negative. Computed tomography imaging of the chest however revealed widespread granulomas: including at the apices and bases of the right lung with suggestion of histoplasmosis. Patient was placed on fluconazole. Patient 4 received plasmapheresis and pulsed steroids. Cytopenias and inflammatory markers continued to worsen in both patient 3 and 4. Fever initially resolved in both patients but both developed disseminated intravascular coagulation shortly after treatment was started with consequent fatality.

**Figure 1** - Bone marrow biopsy (showing macrophage engulfing hematopoietic cells).



**Table 1** - Demographic characteristics, clinical manifestations, laboratory results, and clinical outcomes of the 4 patients with hemophagocytic lymphohistiocytosis.

	Patient 1	2	3	4
Age, years	45	39	60	20
Gender	female	male	male	male
Duration of illness prior to presentation	2 weeks	2 days	1 month	3 months
HLH Diagnostic criteria				
i. Fever (> 38.5 °C):	+	+	+	+
ii. Splenomegaly	+	+	-	-
iii. Cytopenia (affecting ≥ 2 of 3 lineages in peripheral blood)	+	+	+	+
Neutropenia, absolute neutrophil count < 1000/L	+	+	+	-
Anemia, Hb < 9g/dL	+	+	+	+
Thrombocytopenia, Platelet < 100/L	+	+	+	+
iv. Hypertriglyceridemia, TG (fasting ≥ 265 mg/dL) or hypofibrinogenemia, FBRN (≤ 150 mg/dL)	+ (↑TG)	-	+ (↑TG)	+ (↑TG and ↓FBRN)
v. Low or absent NK cells activity	not tested	not tested	not tested	not tested
vi. Hyperferritinemia (≥ 500 µg/L)	+	+	+	+
Ferritin, peak (ng/mL)	55269	2949	4958	87708
vii. High levels of sCD25, a.k.a IL-2Rα (≥ 2400 U/mL)	not tested	not tested	not tested	not tested
viii. Hemophagocytosis in the bone marrow, spleen or lymph nodes	+	+	-	+
Initial presentation				
Tachycardia (HR > 100)	+	+	+	+
Tachypnea (RR > 20)	-	-	+	-
Other features	lymphadenopathy	jaundice, hepatomegaly	mediastinal and hilar lymphadenopathy	lymphadenopathy, skin rash, altered mental status
Underlying and Associated diseases	HIV/AIDS	T cell lymphoma	granulomatous disease likely Histoplasmosis	MAI pneumonia, juvenile rheumatoid arthritis
Other Laboratory results				
LDH (U/L)	564	2354	660	2769
ALP (U/L); initial	238	295	145	113
ALP (U/L); peak	2719	563	358	1049
ANA panel	-	-	-	+
EBV IgM or IgG	+: IgG	+: IgG	no	+: IgM
CMV IgM or IgG	+: IgG	+: IgM and IgG	+: IgG	not tested
Treatment regimen	HLH-2004	hyper CVAD, ICE, ESHAP	RIPE	pulsed steroids and plasmapheresis
Clinical course and outcome				
DIC	-	-	+	+
Cause of death	multi-organ failure	multi-organ failure	multi-organ failure	diffuse cerebral edema and SAH
Survival (days): from diagnosis of HLH	147	54	79	27

MAI: Mycobacterium Avium Intracellulare; ALP: alkaline phosphatase; DIC: disseminated intravascular coagulation; Hyper CVAD: Cyclophosphamide, Vincristine, Adriamycin, Dexamethasone; ICE: Ifosfamide, Carboplatin, Etoposide; ESHAP: Etoposide, methylprednisone, Ara-C (cytarabine); RIPE: Rifampin, Isoniazid, Pyrazinamide, Ethambutol; SAH: subarachnoid hemorrhage; Hb: hemoglobin; HIV: Human immunodeficiency virus infection; IVIG: intravenous immunoglobulin; LDH: lactate dehydrogenase.

### Case reviews and associated diseases

35 case series which included at least 2 adult patients were identified (**table 2**) (16-43,4,44,45,14,46-49). **Table 2** shows the details of these included case reviews, including treatment regimen and patient outcomes. These case series included a range of 2 to 52 adult patients. Any condition that can trigger an inflammatory reaction, infectious or non-infectious, can cause HLH (**table 3**). (50-54) HLH-2004 (or -94) protocol was used in less than half of the cases. However, other chemotherapeutic regimen, such as Cyclophosphamide-Adriamycin-Vincristine-Prednisone (CHOP) were used. This could be due to practice variations and providers experience using certain regimen, or as was

in our case, the frailty of the patients such that the patients were considered too weak to tolerate the chemotherapy regimen recommended. Multiple other therapies directed at the underlying trigger for HLH were used. These included rituximab in most cases where EBV was suspected, plasmapheresis, IVIG, pulsed steroids and antiviral agents. Some patients also had stem cell transplantation (SCT). Mortality ranged from 0 to a 100% over the time period these patients were followed. Mode was 100% mortality and mean was 67%. Remarkably, patients who had SCT had improved survival. Time to death ranged from 5 hours after diagnosis to a patient who was still alive 15 years after SCT for FHL.

**Table 2** - Summary of the case series included in review<sup>1</sup>.

Article	Number of patients reported	Suspected etiology of HLH	Chemotherapeutic regimen and dosage; Adjunct therapy	Mortality rate if reported	Time to death if reported
Park et al <sup>4</sup>	23	EBV, Hepatitis A	HLH-94 or 2004 (dexamethasone, etoposide, and cyclosporine) protocol; corticosteroids, cyclosporine; HSCT	74% in 6 months	Median: 41 days
Tseng et al <sup>5</sup>	96	Viral infections: e.g. CMV, mycobacterial, bacterial: e.g. Aeromonas, and fungi: e.g. cryptococcus; Nosocomial- e.g. burkholderia). Still's disease, SLE, livedoid vasculitis, Sjogren's syndrome, and psoriasis. Hematology / oncology disorders	IVIG, corticosteroids, etoposide	63% 30-day mortality	-
Sieni E et al <sup>6</sup>	11	FHL; Infectious mononucleosis-like illness, Non-Hodgkins lymphoma, neurosarcoïd, Herpes	HLH-94 or HLH-2004 protocols; autologous or allogeneic SCT	64% within 15 years.	ranged from early progressive death shortly after diagnosis -to 10 yrs. 1 patient identified as 'cured' post-SCT
Abe et al <sup>18</sup>	5	Primary EBV; EBV reactivation	chemotherapy with or without etoposide; plasmapheresis (for patient with severe symptoms)	40% mortality over 30 months	-
Argyragi et al <sup>19</sup>	3	EBV; MSSA-Infective endocarditis	corticosteroids, IVIG; intravenous cloxacillin for MSSA endocarditis	0%. All patients alive at 12 months post-diagnosis	-
Ben Dhaou Hmaidi et al <sup>20</sup>	4	Adult-onset Still's disease; Sjogren syndrome; severe sepsis	corticosteroids; other immunosuppressant therapy	50%	unclear
Berry et al <sup>21</sup>	2	EBV infection	IVIG, corticosteroids; antivirals (famciclovir, acyclovir)	100% within a week of admission	5 days

...segue

Article	Number of patients reported	Suspected etiology of HLH	Chemotherapeutic regimen and dosage; Adjunct therapy	Mortality rate if reported	Time to death if reported
Besset et al <sup>22</sup>	9	not reported	etoposide-containing regimen (specifics unknown)	33% died in ICU; 5 (56%) died in hosp	mean ICU LOS: 7 days; mean LOS: 21 days
Bohne et al <sup>23</sup>	2	EBV; Influenza A/H1N1 infection, underlying XLP-1 (SH2D1A) mutation; cerebral aspergillosis	HLH-2004 +rituximab	100%	Death shortly after diagnosis despite treatment
Buyse et al <sup>24</sup>	56	Hematology/oncology disorders (Castleman's dx, B-cell lymphoma, other); Infections: non-viral and viral; 68% of patients had underlying immune-deficiencies	Etoposide, IVIG, corticosteroids	52% while in the hospital	(median hospital LOS: 23.5 [11.2-41.7] days)
Chellapandian et al <sup>25</sup>	42	EBV	HLH-2004 + rituximab; IVIG; antivirals (ganciclovir, acyclovir); allogeneic SCT	38% died within 900 days	-
Fox et al <sup>27</sup>	3	EBV; Hodgkins Lymphoma	-IVIG, rituximab, ganciclovir; immunosuppressant: cyclosporin A, corticosteroid; etoposide	67% within 8 weeks of follow up	-
Fukunaga et al <sup>28</sup>	2	malignancy	low-dose etoposide and vincristine plus prednisolone	0%	still alive 1008 and 232 days after transplantation
Gold et al <sup>29</sup>	2	Rheumatoid arthritis.	corticosteroid, cyclosporine, etanercept, and plasmapheresis; intrathecal methotrexate.	50% within 90-day follow up	24 days
Hu et al <sup>30</sup>	15	Infection- MRSA, CMV, EBV; Autoimmune disease; Malignant lymphoma	COP (HLH-2004 protocol used as salvage therapy in 2 patients); allogeneic-HSCT in a patient with lymphoma	33% at 1-year	-
Kelesidis et al <sup>31</sup>	4	EBV reactivation, Chronic Granulomatous Disease	HLH-2004+rituximab; Ganciclovir, IVIG, cyclosporine	75%	not stated
Lecronier et al <sup>32</sup>	17	Q fever, Meditternean spotted fever	Doxycycline; +/- levofloxacin; IVIG, hydroxychloroquine, corticosteroids	0%	all patients recovered
Loa et al <sup>33</sup>	2	following kidney transplant for FSGS; disseminated histoplasmosis	IV liposomal Amphotericin B, oral itraconazole (for 12 months)	0% in 10-month follow up	-
Machaczka et al <sup>34</sup>	8	CLL, Multiple Myeloma, Waldenstroms, T-cell lymphoma, Hodgkin's Lymphoma	IVIG and corticosteroids; HLH-94 protocol	88% over 13 months of follow up	1 week to 13 months
Mayson et al <sup>35</sup>	2	EBV, T-cell lymphoma	HLH 2004 protocol; IVIG, corticosteroids	0% at 3 weeks post-HLH diagnosis	-

Article	Number of patients reported	Suspected etiology of HLH	Chemotherapeutic regimen and dosage; Adjunct therapy	Mortality rate if reported	Time to death if reported
Miguel et al <sup>36</sup>	2	CMV infection in patient on azathioprine for Crohn's disease	IVIg, corticosteroids, antivirals (ganciclovir, valganciclovir)	0% over 8-and 18-month follow up respectively	-
Mitra et al <sup>37</sup>	3	FHL, tuberculosis, diffuse non-Hodgkin T-cell lymphoma	patient 1: only supportive treatment; patient 2: four-drug anti-mycobacterial for 6 months; patient 3: CHOP protocol	67% over 30-days	median: 14 days
Nieto-Ríos et al <sup>38</sup>	2	Disseminated histoplasmosis; kidney transplant	Amphotericin B and itraconazole; immunosuppressant therapy: alemtuzumab induction and maintenance with mycophenolate and cyclosporine / tacrolimus	50% within 3 days	-
Okabe et al <sup>39</sup>	3	EBV, sarcoidosis	IVIg. Others: infliximab, daclizumab, dexamethasone, and cyclosporine	100% within 12 days	-
Premaratna et al <sup>40</sup>	2	Rickettsial infections: <i>Orientia tsutsugamushi</i> and <i>Rickettsia conorii</i>	Doxycycline	0%	(Hematological recovery in 72-96 hrs of initiating treatment)
Rajagopala et al <sup>41</sup>	10	EBV, leishmania, leptospirosis, Parvo B19, SLE, tuberculosis, invasive mucormycosis	HLH 2004 protocol, corticosteroid, IVIg; Other: antiviral, antimalarial, antimycobacterial TB, amphotericin	70% died in ICU; 80% in-hospital	ICU LOS (5 hrs to 15 days); hosp LOS: 2-21 days
Raschke et al <sup>42</sup>	3	suspected bacterial infection	HLH 2004 protocol	100% mortality	
Re et al <sup>43</sup>	2	Human herpesvirus 8 (HHV-8) / Kaposi sarcoma-associated herpesvirus (KSHV); CMV	IVIg, corticosteroids, antivirals (ganciclovir, acyclovir)	100%	unknown
Shabbir et al <sup>44</sup>	18	haematological malignancies, post-autologous stem cell transplant, infection, rheumatologic illness, sickle cell disease, post-orthotopic liver transplant	Etoposide, IVIg, cyclophosphamide. Immunosuppressants: corticosteroids +/- cyclosporine	72%	median survival: 35 days
Soyama et al <sup>45</sup>	2	chronic hepatitis C infection with HCC, now post liver transplantation; chronic hepatitis B with HCC	IVIg, corticosteroid; GM-CSF, entacavir	100% mortality within 5 months of diagnosis	-
Takeoka et al <sup>46</sup>	2	EBV; T cell lymphoma	patient 1: dexamethasone, acyclovir and etoposide; patient 2: CHOP regimen	100% within 4 months	mean time: 3 months
Ueda et al <sup>47</sup>	16	SLE	intravenous cyclophosphamide. Pulsed corticosteroid, IVIg, plasmapheresis, azathioprine / tacrolimus / rituximab	13%	unknown

Segue...

...segue

Article	Number of patients reported	Suspected etiology of HLH	Chemotherapeutic regimen and dosage; Adjunct therapy	Mortality rate if reported	Time to death if reported
van Langenberg et al <sup>48</sup>	2	CMV infection in patient on azathioprine for inflammatory bowel disease	Ganciclovir; hydrocortisone	0%	patient 1: remains well after 5 year follow up; patient 2: remains well at 16 month follow up
Young et al <sup>49</sup>	4	CMV infection; Hantavirus pulmonary infection; pneumonia with <i>Acinetobacter baumannii</i>	IVIg, corticosteroid, cyclosporine	66% in 47 days	-
Yu JT et al <sup>50</sup>	30	T-cell and B-cell lymphoma	CHOP/CHOP-like +/- Rituximab (for B-cell). Other: hyper-CVAD, ESHAP, steroid only); Allogeneic SCT in three patients	93%	median overall: 231 days. 330 days (B-cell); 93 days (T-cell). 2 patients with T-cell lymphoma and SCT had complete disease remission

<sup>1</sup>Some studies reported only median age. Such studies noted; SCT: stem cell transplantation; LOS: length of stay; HCC: hepatocellular carcinoma; G-CSF: granulocyte colony stimulating factor; CHOP: cyclophosphamide, doxorubicin, vincristine, prednisone.

## Pathogenesis

The key pathogenic feature of HLH is hypercytokinemia. Foreign materials, such as organisms and tumors, activate cytotoxic T lymphocytes (CTL) and natural killer cells (NK) cells. When activated, these cells form secretory lysosomes, which contain perforin and granzyme B. Perforin makes pores in the surface of target cells and granzyme B enters the target cell to stimulate apoptosis. These activated CTL and NK cells also release numerous cytokines including interferon-gamma, Tumor necrosis factor (TNF)-alpha, interleukin-6 (IL-6), and colony-stimulating factor which stimulate bone marrow macrophages (55). In primary HLH, NK cells and CTL fail to eliminate their targets leading to sustained inflammatory response, continued activation of macrophages, and production of cytokines (1). In secondary HLH (sHLH), macrophages are activated as a result of an inciting immunogenic condition or agent. Hypercytokinemia leads to prolonged fevers, fatigue and they down regulate the expression of CD47 on the surface of hematopoietic cells. Self-recognition to prevent phagocytosis is regulated by the CD47-SIRPA (signal regulatory protein) interaction (56,57). Down regulation of CD 47 therefore leads to an imbalance favoring pro-phagocytic factors, such as calreticulin. Macrophages become activated and engulf erythrocytes, leukocytes, platelets, and their precursors in the marrow as well as other cells which might lack CD 47, such as lymphoma cells (58). This engulfment is responsible for cytopenias in patients with HLH.

## Diagnostic criteria (1)

Diagnosis of HLH is made if 5 of the following 8 criteria are met or a molecular defect consistent with HLH is identified (1). Clinical

criteria: fever ( $> 38.5$  °C): usually present in  $> 90\%$  of patients or splenomegaly. Laboratory criteria: cytopenia (affecting 2 of 3 lineages in peripheral blood); hypertriglyceridemia (fasting  $> 265$  mg/dL) or hypofibrinogenemia ( $< 150$  mg/dL); low or absent NK cells activity; hyperferritinemia ( $> 500$  µg/L); and/or high levels of sCD25, also known as IL-2Rα ( $> 2400$  U/mL) which indicates high T-lymphocyte activity. Histopathological criteria: hemophagocytosis in the bone marrow, spleen or lymph nodes with no evidence of malignancy. This is however not a prerequisite for diagnosis. Other laboratory abnormalities that could be present in HLH include EBV IgM or IgG, positive ANA panel, proteinuria from hemophagocytes invading kidney, and high d-dimer (1).

## Treatment regimen

In HLH-2004 guideline (1), the recommended regimen includes cyclosporine, etoposide, dexamethasone as well as intrathecal methotrexate. Other regimens that have been used include: CHOP, Cyclophosphamide-Vincristine-Prednisone (COP), Cyclophosphamide-Etoposide-Dexamethasone (CED). Medications like alemtuzumab, intravenous immunoglobulin (IVIg) and antithymocyte globulin have also been used. SCT should be considered for patients with FHL, EBV-triggered HLH, or refractory HLH. Research has shown that selected patients, such as those with high fibrinogen, could also benefit from SCT. Adjunctive treatment included in the HLH-2004 protocol include: rituximab (to be added to regimen if EBV-HLH since it kills CD-20 positive B-cells), splenectomy (in patients with massive splenomegaly), rFVIIa (in hyperfibrinogenemia and coagulopathy).

**Table 3** - Reported Diseases associated with HLH in Adults.

<b>Infectious</b>	<b>Autoimmune diseases</b> <sup>5,47</sup>	<b>SLE</b>	
Viral <sup>15,18, 21, 23, 25, 31,36</sup>	Epstein Barr Virus	Rheumatoid arthritis	
	HIV/AIDS	Adult onset Stills disease	
	Cytomegalovirus		
	Hepatitis A	Malignancies <sup>34, 50</sup>	
	Parvovirus B19	Primary	T-cell lymphoma
	Mumps virus		B-cell lymphoma
	Herpes Simplex virus		Hodgkin's lymphoma
	HHV-8		Chronic lymphocytic leukemia
	Dengue		Acute myeloblastic leukemia
	H1N1		Primary CNS lymphoma
Fungal <sup>5, 33, 38, 51-53</sup>	Parainfluenza		Anaplastic lymphoma
			Mantle cell lymphoma
	Mycobacterium spp		
	Histoplasmosis	Metastatic	Adenocarcinoma
	Aspergillosis		
	Mucormycosis	Transplant <sup>38, 46</sup>	liver, kidney
	Candidiasis		
Bacterial <sup>5, 32, 40</sup>		Other <sup>5, 22, 26, 36, 39, 42, 48</sup>	Sarcoidosis
	Rickettsia		Burns
	Yersiniosis		Severe trauma
	Brucellosis		DRESS
	Leptospirosis		Sezary syndrome
Protozoan <sup>54, 55</sup>			Inflammatory Bowel Disease
	Toxoplasmosis		Azathioprine
	Leishmaniasis		HAART
			Immune Reconstitution Syndrome

## Prognosis

Prognosis depends on the underlying etiology. Nonetheless, the mortality of sHLH remains poor with most patients dying within 6 months of diagnosis. Death is commonly from multi-organ failure from either the complication of the HLH itself - including susceptibility to infections and bleeding from thrombocytopenia; or complication of the underlying disease - such as opportunistic infections in HIV; or from complications of treatment - commonly chemotherapy agents.

*Favorable prognostic factors* include: children, probably because etiology likely to be FHL; adults < 50 years, shorter time to treatment initiation, fevers subsiding within 3 days of diagnosis, low histiocytes in marrow, higher fibrinogen levels, absence of DIC or other coagulopathy and excellent baseline health.

## Discussion

The overall evidence suggests that HLH is commonly triggered by infections. HLH could be considered a form of systemic inflammatory response syndrome (SIRS) (41). As with infection-triggered SIRS, early suspicion and prompt treatment is needed to avoid fatality. Diagnosis remains a challenge as HLH may initially present similarly to sepsis and many other common conditions. In these case series, all four patients initially presented with subjective fevers and extreme fatigue which had lasted one to three months. These non-specific and poorly localizing symptoms could be present in a wide variety of conditions. However, the duration of these symptoms is unusual for an acute process like bacterial sepsis in which symptoms would be more likely to progress rapidly. Persistent fevers despite an-



tibacterial therapy and negative cultures as well as cytopenias should raise suspicion for HLH. Routine testing for ferritin in patients who meet these criteria might aid in early diagnosis. After the diagnosis of HLH is made, providers have to decide if to target the underlying cause of the inflammatory response or to suppress the hyper-inflammatory response. Given that > 60% of infection-associated HLH (IA-HLH) cases are usually secondary to EBV, it might be safe to assume EBV is the cause of a patient's HLH in the absence of malignancy, autoimmune disease or any other obvious infection (23). The appropriate course of action based on the case reports reviewed is varied. As an example, some instances of EBV-HLH improved with addition of rituximab (to HLH-2004 protocol) suggesting targeting underlying EBV infection was therapeutically advantageous. However, in some instances the patients became sicker with worsening cytopenias following chemotherapy initiation (23). Patient 1 as reported here initially showed good response to HLH-2004 chemotherapy protocol. However, as disease relapsed and patient's health became more tenuous, the risks of further cycles of chemotherapy seemed to outweigh the benefits. Patient 3's poor clinical status at presentation and the rapidly progressing deterioration of the health of patient 4 made initiation of relatively toxic chemotherapy clinically inappropriate. Unfortunately, the outcome of these patients was fatal regardless of the treatment course chosen.

Future directions should include exploring the various mechanisms by which HLH is stimulated so as to aid in the development of more effective strategies. As shown in a recent publication, monoclonal antibodies to CD47 (anti-hCD47 mAb) in vivo led to phagocytic elimination of multiple tumor types and also prevented metastasis (59). Future research on chemotherapeutic targets of the CD47-SIRP $\alpha$  pathway might also lead to discovery of more potent therapies for HLH.

This study adds to the body of the literature by comparing and contrasting the clinical presentation and outcomes of adult patients. The concise review of conditions associated with HLH will also be helpful as clinicians search for the underlying etiology of HLH. In conclusion, HLH is a fatal disease that usually mimics (or is triggered by) other common conditions. Early suspicion and prompt diagnosis is crucial to improved outcomes. Therapy should be individualized considering patient's baseline health, clinical presentation, and the suspected underlying trigger for HLH.

### Abbreviations

HLH, hemophagocytic lymphohistiocytosis; SIRS, systemic inflammatory response syndrome; BM, bone marrow; FHL, familial hemophagocytic lymphohistiocytosis, EBV, Epstein Barr virus; CMV, cytomegalovirus; IVIG, intravenous immunoglobulin; SCT, stem cell transplantation; CTL, Cytotoxic T lymphocytes; NK, natural killer cells.

### References

- Henter JI, Horne A, Arico M, Egeler RM, Filipovich AH, Imashuku S, Ladisch S, McClain K, Webb D, Winiarski J, Janka G (2007) HLH-2004: Diagnostic and therapeutic guidelines for hemophagocytic lymphohistiocytosis. *Pediatric blood & cancer* 48. (2):124-131. doi:10.1002/pbc.21039.
- Trottestam H, Horne A, Arico M, Egeler RM, Filipovich AH, Gadner H, Imashuku S, Ladisch S, Webb D, Janka G, Henter JI, Histiocyte S (2011) Chemoimmunotherapy for hemophagocytic lymphohistiocytosis: long-term results of the HLH-94 treatment protocol. *Blood*. 118(17):4577-84. doi:10.1182/blood-2011-06-356261.
- Parikh SA, Kapoor P, Letendre L, Kumar S, Wolanskyj AP (2014) Prognostic factors and outcomes of adults with hemophagocytic lymphohistiocytosis. *Mayo Clinic proceedings*. 89(4):484-92. doi:10.1016/j.mayocp.2013.12.012.
- Sieni E, Cetica V, Piccin A, Gherlinzoni F, Sasso FC, Rabusin M, Attard L, Bosi A, Pende D, Moretta L, Arico M (2012) Familial hemophagocytic lymphohistiocytosis may present during adulthood: clinical and genetic features of a small series. *PLoS one*. 7(9):e44649. doi:10.1371/journal.pone.0044649.
- Arico M, Imashuku S, Clementi R, Hibi S, Teramura T, Danesino C, Haber DA, Nichols KE (2001) Hemophagocytic lymphohistiocytosis due to germline mutations in SH2D1A, the X-linked lymphoproliferative disease gene. *Blood*. 97(4):1131-3.
- Cetica V, Pende D, Griffiths GM, Arico M (2010) Molecular basis of familial hemophagocytic lymphohistiocytosis. *Haematologica*. 95(4):538-41. doi:10.3324/haematol.2009.019562.
- Cote M, Menager MM, Burgess A, Mahlaoui N, Picard C, Schaffner C, Al-Manjomi F, Al-Harbi M, Alangari A, Le Deist F, Gennery AR, Prince N, Cariou A, Nitschke P, Blank U, El-Ghazali G, Menasche G, Latour S, Fischer A, de Saint Basile G (2009) Munc18-2 deficiency causes familial hemophagocytic lymphohistiocytosis type 5 and impairs cytotoxic granule exocytosis in patient NK cells. *The Journal of clinical investigation*. 119(12):3765-73. doi:10.1172/jci40732.
- de Saint Basile G, Menasche G, Fischer A (2010) Molecular mechanisms of biogenesis and exocytosis of cytotoxic granules. *Nature reviews Immunology*. 10(8):568-79. doi:10.1038/nri2803.
- Feldmann J, Callebaut I, Raposo G, Certain S, Bacq D, Dumont C, Lambert N, Ouachee-Chardin M, Chedeville G, Tamary H, Minard-Colin V, Vilmer E, Blanche S, Le Deist F, Fischer A, de Saint Basile G (2003) Munc13-4 is essential for cytolytic granules fusion and is mutated in a form of familial hemophagocytic lymphohistiocytosis (FHL3). *Cell*. 115(4):461-73.
- Filipovich AH, Zhang K, Snow AL, Marsh RA (2010) X-linked lymphoproliferative syndromes: brothers or distant cousins? *Blood*. 116(18):3398-408. doi:10.1182/blood-2010-03-275909.
- Stapp SE, Dufourcq-Lagelouse R, Le Deist F, Bhawan S, Certain S, Mathew PA, Henter JI, Bennett M, Fischer A, de Saint Basile G, Kumar V (1999) Perforin gene defects in familial hemophagocytic lymphohistiocytosis. *Science*. 286(5446):1957-9.
- zur Stadt U, Rohr J, Seifert W, Koch F, Grieve S, Pagel J, Strauss J, Kasper B, Nurnberg G, Becker C, Maul-Pavicic A, Beutel K, Janka G, Griffiths G, Ehl S, Hennies HC (2009) Familial hemophagocytic lymphohistiocytosis type 5 (FHL-5) is caused by mutations in Munc18-2 and impaired binding to syntaxin 11. *American journal of human genetics*. 85(4):482-92. doi:10.1016/j.ajhg.2009.09.005.

13. zur Stadt U, Schmidt S, Kasper B, Beutel K, Diler AS, Henter JJ, Kabisch H, Schneppenheim R, Nurnberg P, Janka G, Hennies HC (2005) Linkage of familial hemophagocytic lymphohistiocytosis (FHL) .type-4 to chromosome 6q24 and identification of mutations in syntaxin 11. *Human molecular genetics* 14;(6):827-34. doi:10.1093/hmg/ddi076.
14. Tseng YT, Sheng WH, Lin BH, Lin CW, Wang JT, Chen YC, Chang SC (2011) Causes, clinical symptoms, and outcomes of infectious diseases associated with hemophagocytic lymphohistiocytosis in Taiwanese adults. *Journal of microbiology, immunology, and infection. Wei mian yu gan ran za zhi.* 44;(3):191-7. doi:10.1016/j.jmii.2011.01.027.
15. Zhang K, Jordan MB, Marsh RA, Johnson JA, Kissell D, Meller J, Villanueva J, Risma KA, Wei Q, Klein PS, Filipovich AH (2011) Hypomorphic mutations in PRF1, MUNC13-4, and STXBP2 are associated with adult-onset familial HLH. *Blood.* 118;(22):5794-8. doi:10.1182/blood-2011-07-370148.
16. Abe Y, Shiratsuchi M, Nagasawa E, Ohtsuka R, Kiyasu J, Sada E, Idutsu K, Kotoh K, Nishimura J, Ohga S, Takayanagi R (2010) (Five adult cases of Epstein-Barr virus-associated hemophagocytic lymphohistiocytosis). (*Rinsho ketsueki*) The Japanese journal of clinical hematology. 51;(1):74-9.
17. Argyraki CK, Gabeta S, Zachou K, Boulbou M, Polyzos A, Dalekos GN (2011) Favourable outcome of life-threatening infectious-related haemophagocytic syndrome after combination treatment with corticosteroids and intravenous immunoglobulin infusions. *European journal of internal medicine.* 22;(6):e155-7. doi:10.1016/j.ejim.2011.07.010.
18. Ben Dhaou Hmaidi B, Derbali F, Boussema F, Ketari Jamoussi S, Baili L, Kochbati S, Cherif O, Rokbani L (2011) (Hemophagocytic syndrome: report of 4 cases). *La Tunisie medicale.* 89;(1):70-5.
19. Berry PA, Bernal W, Pagliuca A, Sizer E, Salisbury JR, Wendon JA, Auzinger G (2008) Multiple organ failure and severe bone marrow dysfunction in two 18 year-old Caucasian patients: Epstein-Barr virus and the haemophagocytic syndrome. *Anaesthesia.* 63;(11):1249-54. doi:10.1111/j.1365-2044.2008.05584.
20. Besset S, Schnell D, Azoulay E (2012) Hemophagocytic lymphohistiocytosis mimicking septic shock. *Chest.* 141;(3):835; author reply 836. doi:10.1378/chest.11-2717.
21. Bohne S, Kentouche K, Petersen I, Fritzenwanger M, Pletz MW, Lehmborg K, La Rosee P, Guntinas-Lichius O (2013) Fulminant Epstein-Barr virus-associated hemophagocytic lymphohistiocytosis. *The Laryngoscope.* 123;(2):362-5. doi:10.1002/lary.23433.
22. Buyse S, Teixeira L, Galicier L, Mariotte E, Lemiale V, Seguin A, Bertheau P, Canet E, de Labarthe A, Darmon M, Rybojad M, Schlemmer B, Azoulay E (2010) Critical care management of patients with hemophagocytic lymphohistiocytosis. *Intensive care medicine.* 36;(10):1695-702. doi:10.1007/s00134-010-1936-z.
23. Chellapandian D, Das R, Zelle K, Wiener SJ, Zhao H, Teachey DT, Nichols KE (2013) Treatment of Epstein Barr virus-induced haemophagocytic lymphohistiocytosis with rituximab-containing chemo-immunotherapeutic regimens. *British journal of haematology.* 162;(3):376-82. doi:10.1111/bjh.12386.
24. Draper NL, Morgan MB (2007) Dermatologic perivascular hemophagocytosis: a report of two cases. *The American Journal of dermatopathology.* 29;(5):467-9. doi:10.1097/DAD.0b013e3181454047.
25. Fox CP, Shannon-Lowe C, Gothard P, Kishore B, Neilson J, O'Connor N, Rowe M (2010) Epstein-Barr virus-associated hemophagocytic lymphohistiocytosis in adults characterized by high viral genome load within circulating natural killer cells. *Clinical infectious diseases: an official publication of the Infectious Diseases Society of America.* 51;(1):66-9. doi:10.1086/653424.
26. Fukunaga A, Nakamura F, Yoshinaga N, Inano S, Maruyama W, Hirata H, Arima N (2011) Successful treatment with combined chemotherapy of two adult cases of hemophagocytic lymphohistiocytosis in recipients of umbilical cord blood cell transplantation. *International journal of hematology.* 93;(4):551-4. doi:10.1007/s12185-011-0792-0.
27. Gold CA, Sheth SJ, Agarwal S, Claassen J, Foreman B (2015) New-onset seizures in two adults with hemophagocytic lymphohistiocytosis. *Journal of neurology.* 262(4):1063-5. doi:10.1007/s00415-015-7669-8.
28. Hu Y, Xu J, Wang L, Li J, Qiu H, Zhang S (2012) Treatment of hemophagocytic lymphohistiocytosis with cyclophosphamide, vincristine, and prednisone. *Swiss medical weekly.* 142:w13512. doi:10.4414/sm.w.2012.13512.
29. Kelesidis T, Humphries R, Terashita D, Eshaghian S, Territo MC, Said J, Lewinski M, Currier JS, Pegues D (2012) Epstein-Barr virus-associated hemophagocytic lymphohistiocytosis in Los Angeles County. *Journal of medical virology.* 84;(5):777-785. doi:10.1002/jmv.23267.
30. Lecronier M, Prendki V, Gerin M, Schneerson M, Renvoise A, Larroche C, Zioli M, Fain O, Mekinian A (2013) Q fever and Mediterranean spotted fever associated with hemophagocytic syndrome: case study and literature review. *International journal of infectious diseases: IJID: official publication of the International Society for Infectious Diseases.* 17;(8):e629-33. doi:10.1016/j.ijid.2012.12.026.
31. Lo MM, Mo JQ, Dixon BP, Czech KA (2010) Disseminated histoplasmosis associated with hemophagocytic lymphohistiocytosis in kidney transplant recipients. *American journal of transplantation and the American Society of Transplant Surgeons.* 10;(3):687-91. doi:10.1111/j.1600-6143.2009.02969.x.
32. Machaczka M, Vaktas J, Klimkowska M, Hagglund H (2011) Malignancy-associated hemophagocytic lymphohistiocytosis in adults: a retrospective population-based analysis from a single center. *Leukemia & lymphoma.* 52;(4):613-9. doi:10.3109/10428194.2010.551153.
33. Mayson E, Saverimuttu J, Warburton P (2014) Two-faced haemophagocytic lymphohistiocytosis: comparative review of two cases of adult haemophagocytic lymphohistiocytosis. *Internal medicine journal.* 44(2):198-201. doi:10.1111/imj.12347.
34. Miquel T, Bonnet DP, Lepout J, Longuet P, Bletry O, Lepout C (2009) Hemophagocytic syndrome in the course of Crohn's disease: possible association with cytomegalovirus infection. *The American journal of gastroenterology.* 104;(1):252. doi:10.1038/ajg.2008.24.
35. Mitra B, Shrivastav A, Mukherjee K, Ghosh A (2009) Hemophagocytic lymphohistiocytosis: a case series. *Hematology/oncology and stem cell therapy.* 2;(2):367-70.
36. Nieto-Rios JF, Aristizabal-Alzate A, Ocampo C, Serrano-Gayubo AK, Serna-Higuaita LM, Zuluaga-Valencia G (2012) Disseminated histoplasmosis and haemophagocytic syndrome in two kidney transplant patients. *Nefrologia: publicacion oficial de la Sociedad Espanola Nefrologia.* 32;(5):683-4. doi:10.3265/Nefrologia.pre2012.Jun.11508.
37. Okabe T, Shah G, Mendoza V, Hirani A, Baram M, Marik P (2012) What intensivists need to know about hemophagocyt-

- ic syndrome: an underrecognized cause of death in adult intensive care units. *Journal of intensive care medicine*. 27(1):58-64. doi:10.1177/0885066610393462.
38. Park HS, Kim DY, Lee JH, Lee JH, Kim SD, Park YH, Lee JS, Kim BY, Jeon M, Kang YA, Lee YS, Seol M, Lee YJ, Lim YS, Jang S, Park CJ, Chi HS, Lee KH (2012) Clinical features of adult patients with secondary hemophagocytic lymphohistiocytosis from causes other than lymphoma: an analysis of treatment outcome and prognostic factors. *Annals of hematology*. 91(6):897-904. doi:10.1007/s00277-011-1380-3.
  39. Premaratna R, Williams HS, Chandrasena TG, Rajapakse RP, Kularatna SA, de Silva HJ (2009) Unusual pancytopenia secondary to haemophagocytosis syndrome in rickettsioses. *Transactions of the Royal Society of Tropical Medicine and Hygiene*. 103(9):961-3. doi:10.1016/j.trstmh.2009.04.003.
  40. Rajagopala S, Singh N, Agarwal R, Gupta D, Das R (2012) Severe hemophagocytic lymphohistiocytosis in adults-experience from an intensive care unit from North India. *Indian journal of critical care medicine: peer-reviewed, official publication of Indian Society of Critical Care Medicine*. 16(4):198-203. doi:10.4103/0972-5229.106501.
  41. Raschke RA, Garcia-Orr R (2011) Hemophagocytic lymphohistiocytosis: a potentially underrecognized association with systemic inflammatory response syndrome, severe sepsis, and septic shock in adults. *Chest*. 140(4):933-8. doi:10.1378/chest.11-0619.
  42. Re A, Facchetti F, Borlenghi E, Cattaneo C, Capucci MA, Ungari M, Barozzi P, Vallerini D, Potenza L, Torelli G, Rossi G, Luppi M (2007) Fatal hemophagocytic syndrome related to active human herpesvirus-8/Kaposi sarcoma-associated herpesvirus infection in human immunodeficiency virus-negative, non-transplant patients without related malignancies. *European journal of haematology*. 78(4):361-4. doi:10.1111/j.1600-0609.2007.00828.x.
  43. Shabbir M, Lucas J, Lazarchick J, Shirai K (2011) Secondary hemophagocytic syndrome in adults: a case series of 18 patients in a single institution and a review of literature. *Hematological oncology*. 29(2):100-6. doi:10.1002/hon.960.
  44. Soyama A, Eguchi S, Takatsuki M, Hidaka M, Tomonaga T, Yamanouchi K, Miyazaki K, Inokuma T, Tajima Y, Kanematsu T (2011) Hemophagocytic syndrome after liver transplantation: report of two cases. *Surgery today*. 41 (11):1524-30. doi:10.1007/s00595-010-4512-9.
  45. Takeoka Y, Nakamae M, Nakamae H, Hagihara K, Sakamoto E, Nakane T, Koh H, Koh KR, Ohta K, Yamane T, Hino M (2007) Two cases of ampulla (takotsubo-shaped) cardiomyopathy associated with hemophagocytic lymphohistiocytosis. *Acta haematologica*. 117(4):205-10. doi:10.1159/000098461.
  46. Ueda Y, Yamashita H, Takahashi Y, Kaneko H, Kano T, Mimori A (2014) Refractory hemophagocytic syndrome in systemic lupus erythematosus successfully treated with intermittent intravenous cyclophosphamide: three case reports and literature review. *Clinical rheumatology*. 33(2):281-6. doi:10.1007/s10067-013-2451-8.
  47. van Langenberg DR, Morrison G, Foley A, Buttigieg RJ, Gibson PR (2011) Cytomegalovirus disease, haemophagocytic syndrome, immunosuppression in patients with IBD: 'a cocktail best avoided, not stirred'. *Journal of Crohn's & colitis*. 5(5):469-72. doi:10.1016/j.crohns.2011.04.010.
  48. Young P, Peroni J, Finn BC, Venditti JE, Preiti V, Bullorsky E, Bruetman JE (2011) (Hemophagocytic syndrome. Report of four cases). *Revista medica de Chile*. 139(2):224-9. doi:S0034-98872011000200013.
  49. Yu JT, Wang CY, Yang Y, Wang RC, Chang KH, Hwang WL, Teng CL (2013) Lymphoma-associated hemophagocytic lymphohistiocytosis: experience in adults from a single institution. *Annals of hematology*. 92(11):1529-36. doi:10.1007/s00277-013-1784-3.
  50. Balkis MM, Bazzi L, Taher A, Salem Z, Uthman I, Kanj N, Boulos FI, Kanj SS (2009) Severe hemophagocytic syndrome developing after treatment initiation for disseminated Mycobacterium tuberculosis: case report and literature review. *Scandinavian journal of infectious diseases*. 41(6-7):535-7. doi:10.1080/00365540902978075.
  51. Chou YH, Hsu MS, Sheng WH, Chang SC (2010) Disseminated Mycobacterium kansasii infection associated with hemophagocytic syndrome. *International journal of infectious diseases: IJID: official publication of the International Society for Infectious Diseases*. 14(3):e262-264. doi:10.1016/j.ijid.2009.04.017.
  52. Su NW, Chen CK, Chen GS, Hsieh RK, Chang MC (2009) A case of tuberculosis-induced hemophagocytic lymphohistiocytosis in a patient under hemodialysis. *International journal of hematology*. 89(3):298-301. doi:10.1007/s12185-009-0265-x.
  53. Singh G, Shabani-Rad MT, Vanderkooi OG, Vayalumkal JV, Kuhn SM, Guilcher GM, Steele M (2013) Leishmania in HLH: a rare finding with significant treatment implications. *Journal of pediatric hematology/oncology*. 35(3):e127-9. doi:10.1097/MPH.0b013e318286d619.
  54. Arayici S, Sari FN, Yarali N, Oncel MY, Kadioglu Simsek G, Uras N, Dilmen U (2014) Toxoplasmosis-associated hemophagocytosis in a preterm newborn. *Turkish journal of haematology: official journal of Turkish Society of Haematology*. 31(3):309-10. doi:10.4274/tjh.2013.0379.
  55. Akashi K, Hayashi S, Gondo H, Mizuno S, Harada M, Tamura K, Yamasaki K, Shibuya T, Uike N, Okamura T, et al. (1994) Involvement of interferon-gamma and macrophage colony-stimulating factor in pathogenesis of haemophagocytic lymphohistiocytosis in adults. *British journal of haematology*. 87(2):243-50.
  56. Brown EJ, Frazier WA (2001) Integrin-associated protein (CD47) and its ligands. *Trends in cell biology*. 11(3):130-5.
  57. Matozaki T, Murata Y, Okazawa H, Ohnishi H (2009) Functions and molecular mechanisms of the CD47-SIRPalpha signaling pathway. *Trends in cell biology*. 19(2):72-80. doi:10.1016/j.tcb.2008.12.001.
  58. Kuriyama T, Takenaka K, Kohno K, Yamauchi T, Daitoku S, Yoshimoto G, Kikushige Y, Kishimoto J, Abe Y, Harada N, Miyamoto T, Iwasaki H, Teshima T, Akashi K (2012) Engulfment of hematopoietic stem cells caused by down-regulation of CD47 is critical in the pathogenesis of hemophagocytic lymphohistiocytosis. *Blood*. 120(19):4058-67. doi:10.1182/blood-2012-02-408864.
  59. Willingham SB, Volkmer JP, Gentles AJ, Sahoo D, Dalerba P, Mitra SS, Wang J, Contreras-Trujillo H, Martin R, Cohen JD, Lovelace P, Scheeren FA, Chao MP, Weiskopf K, Tang C, Volkmer AK, Naik TJ, Storm TA, Mosley AR, Edris B, Schmid SM, Sun CK, Chua MS, Murillo O, Rajendran P, Cha AC, Chin RK, Kim D, Adorno M, Raveh T, Tseng D, Jaiswal S, Enger PO, Steinberg GK, Li G, So SK, Majeti R, Harsh GR, van de Rijn M, Teng NN, Sunwoo JB, Alizadeh AA, Clarke MF, Weissman IL (2012) The CD47-signal regulatory protein alpha (SIRPalpha) interaction is a therapeutic target for human solid tumors. *Proceedings of the National Academy of Sciences of the United States of America*. 109(17):6662-7. doi:10.1073/pnas.1121623109.