

F. SUNZINI, C. BARBATO, C. CANOFARI, L. LUGARI, R. PERRICONE, A. BERGAMINI

Clinical and radiological signs of ABPA associated with airways infection with *Aspergillus* in the absence of specific IgE

Rheumatology, Allergology and Clinical Immunology, Department of “Medicina dei Sistemi”,
University of Rome Tor Vergata, Rome, Italy

KEY WORDS

Aspergillus; allergic
bronchopulmonary aspergillosis; IgE

Corresponding Author

Flavia Sunzini
Università degli Studi di Roma Tor
Vergata
Rome, Italy
E-mail: flavia.sunzini@gmail.com

Summary

Allergic bronchopulmonary aspergillosis (ABPA) is a hypersensitivity reaction to *Aspergillus* that mainly affects patients with asthma. For diagnosis, elevated serum IgE level are needed according to Greenberger and Patterson criteria. We report a case of 43 years-old woman who developed ABPA with productive cough, fever and radiological findings of multiple confluent areas of consolidation in both upper lobes. Laboratory tests showed elevated peripheral eosinophil counts ($9.3 \times 10^3/\text{ml}$). In bronchial washing *A. galactomannans* and *A. Fumigatus* were isolated, although we found normal levels of serum IgE, and the absence of serum IgG and IgE antibodies to *Aspergillus* and *A. galactomannans*. In conclusion, clinical and radiological signs of ABPA can be associated with *Aspergillus* infection also in the absence of a specific serum antibody reaction.

Introduction

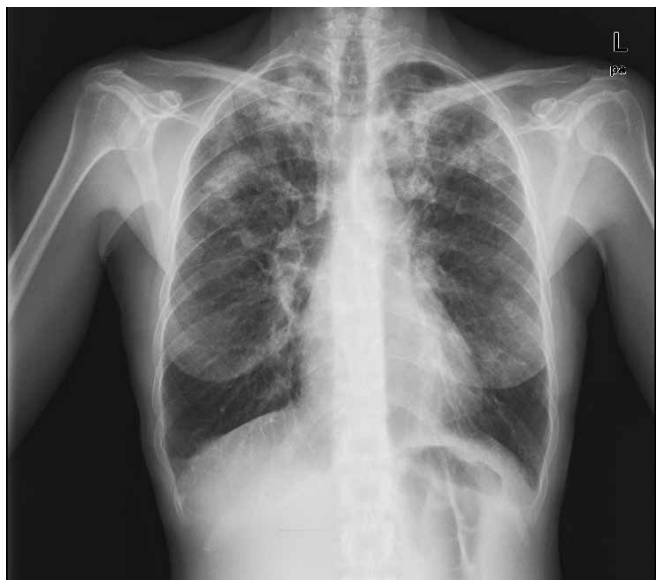Aspergillus, like other filamentous fungi, is primarily acquired from an inanimate reservoir, usually by the inhalation of airborne spore, leading to a variety of clinical syndromes, ranging from aspergilloma in patients with lung cavities, to chronic necrotizing aspergillosis in those who are mildly immunocompromised (1). Invasive pulmonary aspergillosis is a severe disease that is seen in immunocompromised patients, while allergic bronchopulmonary aspergillosis is a hypersensitivity reaction to *Aspergillus* antigens that mainly affects patients with severe asthma (1).

Case Report

A 43 years-old non-smoker woman was referred to us for further evaluation of cough, dyspnea, fever, and peripheral pulmonary infiltrates. The patient had been well until about seven years be-

fore, when she started working in an open dusty environment. Subsequently, the patient experienced persistent rhinitis and several episodes of dyspnea. Lung function tests showed a modest obstructive ventilatory defect with a negative airway reversibility test; a chest X-ray (September 2012) was normal. The patient was diagnosed with asthma and allergic rhinitis and was treated with inhaled corticosteroids and bronchodilators, without benefits. Six months before admission, on August 2014, persistent cough and wheezing were developed. Laboratory tests showed serum IgE levels of 18 IU/ml (normal values, 0-180 IU/ml), elevated peripheral eosinophil counts ($2.2 \times 10^3/\text{mm}^3$); a prick test for pollens and inhalants, including *Aspergillus* was negative; the pulmonary function test was slightly reduced, showing a forced vital capacity (FVC) of 1.95 L (63% of predicted value), forced expiratory volume in 1 sec (FEV1) of 1.27 L (48% of predicted value), and FEV1/FVC of 65.35 (81% of predicted value), 64.7 (80% of predicted value) after airway reversibility test. With-

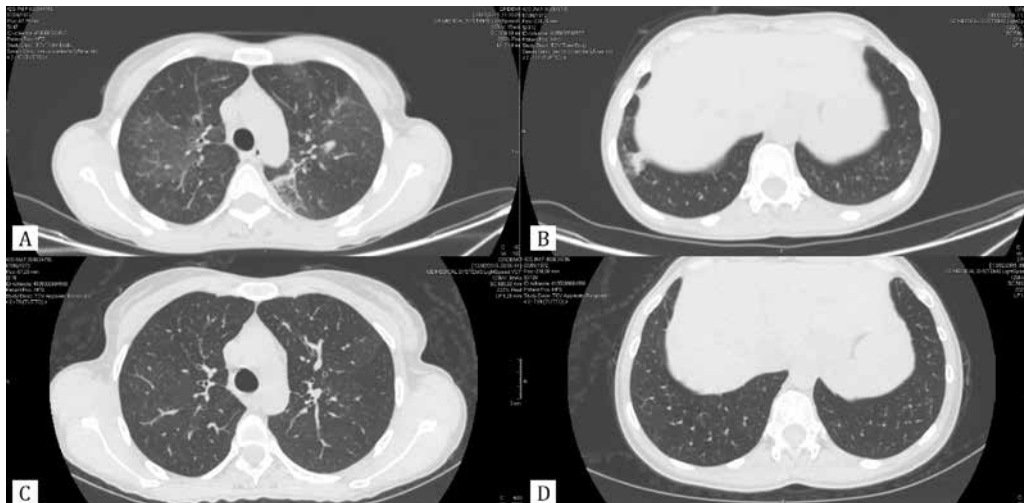
Figure 1 - Chest X-ray showed a parenchymal consolidation on the apex bilaterally and diffuse broncho-vascular markings of lungs.



in six months, the symptoms remained stable up to one week before admission, when fever (> 38°C) developed with worsening cough and dyspnea. On admission, the patient complained of productive cough. On physical examination, she had coarse

breathing sounds with crackles and wheezing in both lower lung fields. On laboratory test, the patient had hemoglobin of 12 g/dl, white blood cell counts $19.9 \times 10^3/\text{ml}$ with 33.6% neutrophils, 15.4% lymphocytes, 46.9% eosinophils ($9.3 \times 10^3/\text{ml}$) and 3.9% monocytes. On serum biochemistry, she had normal liver kidney and electrolyte profile, a reactive C protein of 25.76 mg/L (normal values, 0-3 mg/L), normal levels of neutrophilic cytoplasmic antibodies, angiotensin converting enzyme. Serum IgG antibodies to *Aspergillus* and serum *Aspergillus* galactomannans were absent. Total IgE levels were 11.3 UI/ml (normal values, 0-87 UI/ml) and specific IgE were absent. Arterial blood gas analysis on room air showed pH of 7.50, PaO_2 54 mmHg, PaCO_2 30 mmHg, HCO_3^- 23.4 mmol/L, and SaO_2 of 93.1%. On chest radiography, the patient had multiple confluent areas of consolidation in both upper lobes (**figure 1**). On chest CT scan the patient had ground glass opacities in both upper lobes and in right lower lobe (**figure 2a-b**). Neither pleural effusion nor bronchiectasis were present. A bronchoscopy was performed. This showed no macroscopic lesions, diffusely hyperemic mucosa and many yellowish tenacious secretions. On bronchial washing no malignant cells were observed. Bacterial culture test, *Mycobacterium Tuberculosis* complex and atypical mycobacteria polymerase chain reaction (PCR) were negative. At the microscopic examination, leukocytes, squamous epithelial cells and fungal hyphae were observed. The *Aspergillus* galactomannans from washing was positive, *A. fumigatus* was isolated from bronchial washing. Peripheral blood eosinophilia, pulmo-

Figure 2 - Thorax-CT with contrast before treatment showed a diffuse pseudo-nodular interstitial thickening with ground-glass appearance, mainly present in the upper lobes bilaterally and right lower lobe (A-B). It was also possible to see a parenchymal consolidation in the left pulmonary apex and a small nodular lesion in the upper right lobe. No signs of pleural effusion or lymphadenopathies in the mediastinum area were present. After two weeks of therapy it has been possible to see a resolution of parenchymal consolidation and ground-glass areas reported in the previous CT (C-D).



nary infiltrates and growth of *A. fumigatus* from bronchial washing suggested allergic bronchopulmonary aspergillosis (ABPA) (2). We started steroids at 1 mg/kg/day and voriconazole was added to her regimen. Two weeks later, the symptoms were improved. This was accompanied by the chest CT findings showing disappearance of the pulmonary infiltrates (**figure 2c-d**). Steroids were gradually tapered over a period of two months and the evolution was good.

Discussion

ABPA is a hypersensitivity reaction to *Aspergillus* antigens, mostly due to *A. Fumigatus*. It is typically seen in patients with long-standing asthma or cystic fibrosis. Greenberger and Patterson recently modified the diagnostic criteria for ABPA (3). Not all of these criteria need to be present to diagnose ABPA. The minimal criteria for diagnosis are asthma, immediate skin reactivity to *Aspergillus*, serum IgE level > 1,000 ng/mL, history of pulmonary infiltrates, and elevated levels of serum IgE and IgG antibodies to *A. Fumigatus* (3,4). Some aspects of this case are controversial and deserve to be addressed. First, ABPA is a syndrome seen in patients with severe obstructive lung disease, most commonly asthma (2). Our patient had only a mild obstructive lung defect developed after she started working in an open dusty environment, when she was possibly exposed to *Aspergillus* spores. Second, in atopic individuals, exposure to fungal antigens causes the formation of IgE antibodies directed at the antigen, re-exposure will then result in mast cell degranulation and eosinophilic infiltration (5). However, our patient had normal levels of total IgE, which suggested that she was not an atopic individual. Third, and more important, she did not have specific IgE or IgG. Specific IgE-mediated type I and specific IgG-mediated type III hypersensitivity reactions are proposed to play

an important role in the immunopathogenesis of ABPA caused by *A. fumigatus* (6). Elevated aspergillus-specific IgE levels are a hallmark of ABPA. However, ABPA has been described in a child with cystic fibrosis and low serum IgE levels (7), and in an adult with concomitant common variable hypogammaglobulinemia (8). Thus, in unusual circumstances, the clinical and laboratory features of ABPA may be present in the absence of increased IgE.

Conclusions

In conclusion, clinical and radiological signs of ABPA can be associated with airways infection with *Aspergillus* also in the absence of a specific serum antibody reaction.

References

1. Segal BH. Aspergillosis. N Engl J Med. 2009;360(18):1870-84.
2. Agarwal R. Allergic bronchopulmonary aspergillosis. Chest. 2009;135(3):805-26.
3. Greenberger PA, Patterson R. Diagnosis and management of allergic bronchopulmonary aspergillosis. Ann Allergy. 1986;56(6):444-8.
4. Mintzer RA, Rogers LF, Kruglik GD, Rosenberg M, Neiman HL, Patterson R. The spectrum of radiologic findings in allergic bronchopulmonary aspergillosis. Radiology. 1978;127(2):301-7.
5. Greenberger PA. Immunologic aspects of lung diseases and cystic fibrosis. JAMA. 1997;278(22):1924-30.
6. Slavin RG, Fischer VW, Levine EA, et al. A primate model of allergic bronchopulmonary aspergillosis. Int Arch Allergy Appl Immunol. 1978;56(4):325-33.
7. Maiz L, Cuevas M, Quirce S, et al. Allergic bronchopulmonary aspergillosis with low serum IgE levels in a child with cystic fibrosis. J Allergy Clin Immunol. 1997;100(3):431-2.
8. Schwartz HJ, Berger M, Hostoffer R. Allergic bronchopulmonary aspergillosis and common variable hypogammaglobulinemia in an adult male patient: case report. J Allergy Clin Immunol. 1996;98(3):708-10.