

A. GRAZIANI¹, O. QUERCIA², F. GIRELLI³, A. MARTELLI¹, F. MIRICI CAPPÀ¹, G.F. STEFANINI¹

Omalizumab treatment in patient with severe Asthma and Eosinophilic Granulomatosis with Polyangiitis. A case report

¹UO Medicina Interna, Ospedale degli Infermi, Faenza, Italia

²Ambulatorio Alta Specializzazione in Allergologia, Ospedale degli Infermi, Faenza, Italia

³Servizio di Reumatologia Ospedale GB Morgagni, Forlì, Italia

KEY WORDS

Eosinophilic Granulomatosis with Polyangiitis (EGPA); Asthma; Omalizumab; eosinophilia

Corresponding author

Alessandro Graziani
Medicina Interna, Ospedale Infermi
Faenza, Italy
AUSL Ravenna
Phone: +39 054 660 12 14
E-mail: alessandro.graziani@ausl.ra.it

Summary

Eosinophilic Granulomatosis with Polyangiitis (EGPA), formerly named Churg Strauss Syndrome, is a multisystem disorder characterized by chronic rhinosinusitis, asthma, and prominent peripheral blood eosinophilia; it is classified as a vasculitis of the small and medium sized arteries, although the vasculitis is often not clinically apparent in the initial phases of the disease. We present the case of a woman with EGPA who was frequently treated with high dose steroid therapy during hospital admission for refractory asthma. After December 2008, the date when we started Omalizumab, we observed a significative reduction of circulating eosinophils and IgE serum level, and the patient was no more hospitalized for respiratory failure or asthma attacks.

Introduction

Eosinophilic Granulomatosis with Polyangiitis is a systemic disease characterized by small-medium vessels vasculitis, asthma, peripheral blood eosinophilia and constitutional symptoms with a morbidity rate of 2.4-6.8/million among the general population; necrotizing lesions of the upper airway are not frequently observed. It was first distinguished from classic Polyarteritis Nodosa in 1951 by Jacob Churg and Lotte Strauss (1,2). The disease typically affects patients between 40 and 60 years (mean 48), many of which having a prodromal stage with atopic disease in the upper respiratory tract, followed by asthma and features of cutaneous vasculitis, i.e. subcutaneous nodules, purpura, erythematous rash (3). Asthma often improves when treatment for EGPA is started (4), but some patients may persistently complain of an airflow obstruction due to uncontrolled asthma, despite the immunosuppressive treatment and the clin-

ical remission of EGPA (5). We describe the case of a woman with a five years history of allergy to dust mites, asthma and EGPA, who was frequently treated with high dosage corticosteroids during the admissions for refractory asthma and in which the introduction of Omalizumab induced a reduction of asthma attacks, peripheral eosinophilia and IgE levels, even if corticosteroids were tapered to very low dosage.

Case report

In 2004, a 56 years old female with an history of atopic rhinitis seldom complicated by mild asthma attacks and high level of IgE specific for grass and dust mites, had a sub-arachnoid hemorrhage due to ruptured aneurysm of anterior communicating artery. A complete neurological recovery was reached after several months of rehabilitation. Five months after discharge, she was hospitalized for the first severe asthma attack. Laboratory

disclosed: erythrocyte sedimentation rate 45 mm/1^oh, C-reactive protein 14.5 mg/dl (< 0,5), hemoglobin 12.0 g/dl, white blood cell count 12.7 10⁹/l with 22% eosinophils (calculated eosinophils were 2.8 10⁹/l), platelet count 561 10⁹/l. Other routine biochemical tests, including renal and liver tests, C3 and C4 complement factors, protidogram, and Immunoglobulin G/A/M levels were normal. Blood cultures, urinalysis, serologic test for viral and bacterial infections (cytomegalovirus, influenza viruses, HCV and HBV, Mycoplasma pneumoniae and Chlamydia pneumoniae, Legionella) were negative. Among non organ-specific autoantibodies, we found high levels of ANCA-MPO with 246.4 IU/l (< 7), while cyclic citrullinated peptide antibodies, ANA test, anti-ENA, anti-Cardiolipins, LAC, and cryoglobulins were absent. Serum IgE levels were elevated: 3365 IU/ml (N < 20). Due to the presence of upper and lower paresthesias, we performed an electromyogram, which showed features of mononeuritis multiplex involving peroneal and sural nerves at the right side. Lung CT-scan showed bilateral patchy non-cavitated pulmonary infiltrates; bronchoalveolar lavage demonstrated a high number of eosinophils (30%), excluding bacterial, mycobacterial and fungal infection. An airflow limitation with improvement after administration of inhaled bronchodilator was revealed by spirometry (**figure 1, panel C**). A diagnosis of EGPA was made. In the light of reported family history of breast cancer, we chose parenteral prednisone (1 mg/kg/day) as an immunosuppressive treatment leading to a progressive clinical and radiological improvement. Patient was discharged with the indication to take oral prednisone, inhaled fluticasone and formoterol at daily dosages of 25 mg, 1000 mcg and 24 mcg per day respectively. In 2006 and 2007 she was admitted many times at our Internal Medicine Unit for severe recurrent asthma attacks, requiring high doses of steroid therapy (up to 1 mg/kg/day methylprednisolone). In December 2008, on the basis of some clinical evidence, treatment with Omalizumab (150 mg every two weeks) was started. A significant persistent reduction of IgE levels, p-ANCA and peripheral eosinophil levels was observed; oral and inhalatory steroid doses were progressively reduced to 5 mg/day of prednisone and 250 mcg/day of fluticasone, with no more asthma attacks. Over the next five years of therapy the patient was no longer hospitalized for asthma attacks or respiratory failure. Despite the respiratory improvement, the peripheral nerve complications and the FEV1 value were unaffected.

Discussion

The prominent clinical problem of our patient were frequent asthma attacks, with a family history of cancer that made us reluctant to prescribe immunosuppressive drugs other than steroids. The episodes required frequent hospital admissions, and consequent high IV doses of prednisone. Omalizumab is

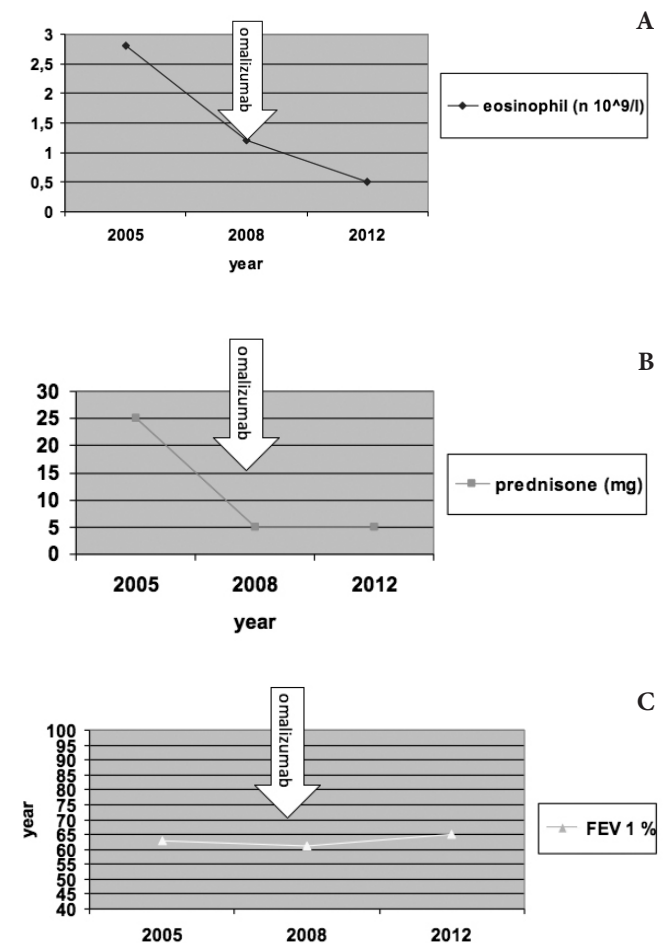
Figure 1 - Time course of eosinophil count, steroid dose and FEV1.

Panel A, B, C: X values= years

Panel A: Y values= eosinophil count (number/l)

Panel B: Y values= prednisone doses (mg)

Panel C: Y values= FEV1 in percentage of predicted values



effective in allergic asthmatic patients (8) with no report of malignancy. Some trials of Omalizumab treatment of asthma in EGPA patients, not fully responders to immunosuppressive regimen, have been published with conflicting results (6,7,10,11). In particular Giavina-Bianchi (7) and Bargagli (10) described positive outcomes with this treatment, while Ruppert (11) and Wechsler (6) reported new cases of EGPA in asthmatic patients during therapy with Omalizumab treatment. The latter could be explained by a reduction of immunosuppressive treatment that masked a previous EGPA, as occurred in anti-leukotriene therapeutic trials (9). We had a good clinical response because our patient continued steroid therapy, systemic and inhaled, at very low dosage (prednisone 5 mg/day); furthermore she was no

more admitted for more than five years despite an unchanged FEV1, probably due to an advanced bronchial remodeling. On the biological point of view, the introduction of Omalizumab led to the normalization of circulating eosinophils and p-ANCA, a fact that was more evident than serum IgE reduction, already induced and maintained by steroids. The effectiveness of Omalizumab on circulating eosinophils seems to be due to an increased apoptosis together with a reduction of IL-2 and IL-13 and GM-CSF production by lymphocytes (8). This pleiotrophism is probably the reason for the substantial anti-inflammatory effect of Omalizumab. Other clinical observations or clinical trials could better explain why some patients showed a good response, while others didn't.

References

1. Churg J, Strauss L. Allergic granulomatosis, allergic angiitis and periarteritis nodosa. *Am J Pathol.* 1951;27:277-301.
2. Szczeklik W, Jakiela R, Adamek D, et al. Cutting Edge issues in the Churg Strauss syndrome. *Clin Rev Allergy Immunol.* 2013;44:39-50.
3. Eustace JA, Nadasdy T, Choi M. Churg Strauss Disease. *J Am Soc Nephrol.* 1999;10:2048-55.
4. Szczeclic W, Sokolowska BM, Zuk J, Mastalerz L, et al. The course of asthma in Churg-Strauss Syndrome. *J Asthma.* 2011;48(2):183-7.
5. Cottin V, Khouatra C, Dubost R, Glerant JC, Cordier JE. Persistent airflow obstruction in asthma of patients with Churg-Strauss syndrome and long-term follow-up. *Allergy.* 2009;64(4):589-95.
6. Wechsler ME, Wong D, Miller MK, Miyasaki LL. Churg Strauss Syndrome in patients treated with Omalizumab. *Chest ME Wechsler.* 2009;136:507-18.
7. Giavina-Bianchi P, Agondi R, Kalil J. One year administration of anti-IgE to a patient with Churg-Strauss-Syndrome. *Int Arch Allergy Immunology.* 2008;146:176-8.
8. Noga O et al. Effect of omalizumab treatment on peripheral eosinophil and T-lymphocyte function in patients with allergic asthma. *J Allergy Clin Immunol.* 2006;117:1493-9.
9. McDanel DL, Muller BA. The linkage between Churg-Strauss syndrome and leukotriene receptor antagonists: fact or fiction? *Therapeutics and Clinical Risk Management.* 2005;1(2):125-40.
10. Bargagli E, Rottoli P. Omalizumab treatment associated with Churg-strauss vasculitis. *Int Arch Allergy Immunol.* 2007;145:268.
11. Ruppert AM et al. *J. Allergy Clin. Immunol.* 2008;121(1):253-4.