

M.A. REYAZULLA<sup>1</sup>, A.L. GOPINATH<sup>1</sup>, N. VAIBHAV<sup>2</sup>, R.P. RAUT<sup>2</sup>

# An unusual complication of late onset allergic contact dermatitis to povidone iodine in Oral & Maxillofacial Surgery – A report of 2 cases

<sup>1</sup>Assoc. Professor, Department Of Oral And Maxillofacial Surgery, Vokkaligara Sangha Dental College & Hospital And Research Centre, Kr Road, Vvpuram, Bangalore, India

<sup>2</sup>Junior Resident, Department Of Oral And Maxillofacial Surgery, Vokkaligara Sangha Dental College & Hospital And Research Centre, Kr Road, Vvpuram, Bangalore, India

## KEY WORDS

*Allergic dermatitis; povidone iodine (PVP-I)*

## Corresponding author

Vaibhav N.  
Department of Oral and Maxillofacial Surgery  
Vokkaligara Sangha Dental College &  
Hospital and Research Centre  
Kr Road, Vvpuram  
Bangalore, India  
vaibhavn86@gmail.com  
Mobile phone: + 91 9844 258 076

## Summary

**Background.** Povidone iodine (PVP-I) is a chemical complex of polyvinylpyrrolidone (also known as povidone or PVP) and elemental iodine. Iodine containing compounds are widely and commonly used as antiseptics and disinfectants. They are available in various forms like aqueous solution, tincture, aerosol, ointment, or foam. Skin irritation to them is due to the oxidative effects of iodine. Because of the low free iodine concentration in povidone-iodine, skin irritation is less frequent from short contact (1). **Case.** We report two cases, both with no history of allergy to any drugs, who developed an allergic reaction 24 hours after the usage of povidone iodine as a pre-operative antiseptic to prepare (scrub) the lower third of face before surgical removal of third molars. This case report was granted an exemption by the ethical committee of our institution review board. The Helsinki declaration doesn't apply to this case presentation. **Conclusion.** PVP-I is the most commonly used antiseptic scrubbing solution prior to most surgeries. However, allergic contact dermatitis due to PVP-I has not been extensively documented or reported and hence under evaluated, compared to other commonly encountered allergens. There is almost general agreement to the proposition that PVP-I is a very rare sensitizer (2,3) though there are some conflicting reports on the matter. However, sometimes when prolonged skin contact with PVP-I occurs when used as a pre-operative antiseptic agent, it can cause allergic dermatitis (4,5). Does this finding make pre-operative testing for allergies to PVP-I necessary in all patients? A point to ponder.

## Introduction

Povidone iodine preparations were introduced in the 1960s and are now the most common iodophor in clinical use because of their broad antimicrobial spectrum of activity, and unrivalled antiseptic properties. They are available in different formulations including solutions, creams, ointments, sprays and wound dressings. Povidone is a polymer similar to dextran and it acts as a carrier that delivers complexed diatomic iodine, which is bactericidal. It affects the structure and functions of enzymes and cell proteins. It also damages bacterial cell function by blocking

hydrogen bonding and altering the membrane structure. These multiple modes of action ensure the rapid death of microbes, and also importantly help to prevent the development of bacterial resistance (6). Acute or late onset allergic contact or irritant dermatitis due to povidone-iodine is a rare complication, especially keeping in mind the extensive usage of the same. Systemic reactions to povidone-iodine are rare, but there are case reports of generalised urticaria and even anaphylactic shock (7,8). These cases have the characteristics of IgE-mediated reactions and in one case specific IgE against povidone was found.

## Cases

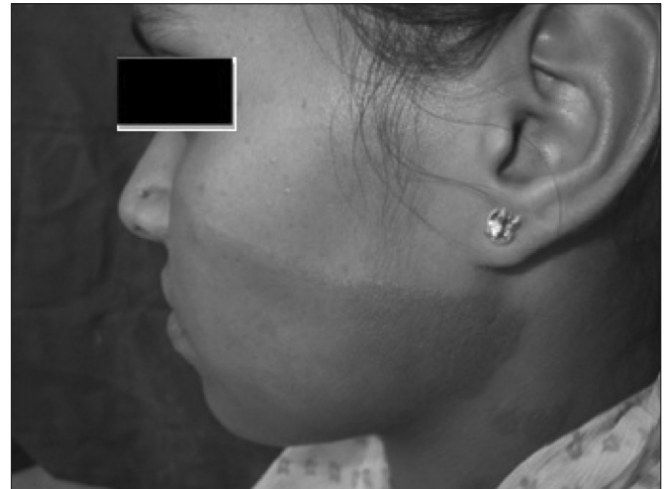Two patients reported to the Department of Oral & Maxillofacial Surgery with a chief complaint of pain in lower back tooth region of jaw. A detailed case history of both the patients was recorded and it did not reveal any history of systemic disorders including asthma or allergy to any medication. Routine blood investigations were carried out, which were within normal limits. Preoperative orthopantomogram was ordered, which showed partially erupted lower third molars with inflamed pericoronal flap. Surgical removal of third molars was decided as a treatment plan for both the patients.

Patients were positioned on dental chair in semi-reclined position and face was first scrubbed with savlon. The savlon was then wiped using sterile gauze. The face was then painted with 5% povidone iodine solution and draped with a sterile cloth, as a part of the standard protocol followed preoperatively before surgical removal of third molars. The procedure in both cases was carried out as planned (based on the evidence provided by the orthopantomogram regarding the position of the offending tooth) without any unforeseen complication. The average duration for the procedure was approximately 45 minutes. Standard post-operative antibiotics and analgesics (Amoxicillin 500 milligrams and Diclofenac sodium 50 mg, paracetamol 325 mg) were prescribed. Both the patients were not given pre-operative or post-operative IV steroid because, as per the evidence provided by the orthopantomogram, excessive bone guttering or soft tissue retraction wasn't needed during the procedure.

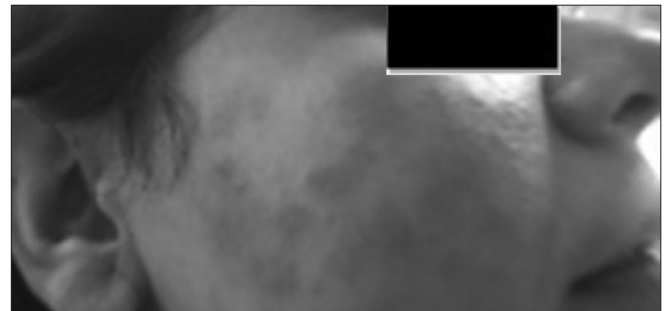
Both the patients reported 24 hrs after the procedure with complaint of rashes only over the face, in the region painted with the PVP1 solution prior to the surgical removal. The patient first noted a stinging or burning sensation, with the onset of erythematous plaques that spread on both sides of the face over cheek region. On further clinical examination, a diffuse erythematous patch over the face, which was slightly oedematous with follicular elevations looking like tiny papules, were observed in both the patients. The erythematous patches were confined only to the areas which were painted with 5% povidone iodine. Although intra-oral irrigation was done using the same solution (a diluted solution 1:10 with normal saline) there were no inflammatory or allergic reactions seen intra-orally. Both the patients were referred to a dermatologist, and the diagnosis arrived at in both the instances was contact allergic dermatitis due to povidone iodine, for which both the patients were advised to use a desquamating soap; topical and systemic steroids as well as systemic antihistamines were prescribed (Systemic antihistamines Tab Cetrizine 10 mg bid, Tab Dazit 5 mg once daily, Inj Dexona 4 mg and vitamin E ointment (Evion cream) for local application). Both the patients were advised to avoid exposure to sunlight to prevent aggravation of the symptoms. With this treatment protocol, case 1 took 10 days to show

complete regression of the symptoms, whereas only 1 week was sufficient for the symptoms to subside in case 2.

*Figure 1 - Case 1.*



*Figure 2 - Case 2.*



## Discussion

Povidone-iodine 5% is a compound of iodine (0.5% releasable iodine but only 0.001% free iodine) and povidone, with additives of glycerin, nonoxynol-9, disodiumphosphate, citric acid, and polyoxyethylene nonylphenyl ether. It is commonly used as an antibacterial agent and antiseptic. Povidone itself is also used in products such as foods, medicaments, hair cosmetics, and toothpastes (9). Povidone is a synthetic polymer used as a suspending agent for many pharmaceutical products, including iodine. In this form, povidone-iodine is a commonly used antiseptic in a variety of surgical cases, providing a broad spectrum of germicidal properties against a wide range of bacteria, viruses, fungi, protozoa, and spores. Systemic absorption after topical

application can potentially lead to immunoglobulin E (IgE) mediated allergic reactions. In its most benign form, local skin pruritus and irritation occur and resolve shortly after removal of povidone-iodine from skin (10). More severe reactions to povidone-iodine leading to anaphylaxis have also been seen in patients with an allergy to components of povidone-iodine. Less commonly reported are cases of angioedema immediately after contact with povidone-iodine (11). Regardless of the severity of symptoms, most reported reactions have developed immediately after exposure to povidone-iodine, representing the early phase of an IgE-mediated allergic reaction. Fewer cases of late phase allergic reactions have been reported with symptoms presenting 6-8 hours after exposure (12). Unique in our cases were that our patient did not have any history of allergic reaction and exhibited no immediate signs of a reaction after exposure to the agent. Their symptoms became apparent almost 24 hours after exposure to povidone-iodine. This is the most commonly used antiseptic scrubbing solution used prior to surgeries. Every clinician should be aware of the potential allergic reaction that the solution may cause (and in some cases due to prolonged exposure). Most clinical setups have a protocol to test for safety of the local anesthetic solution for a particular patient by giving the so called 'test dose' subcutaneously prior to the procedure. The question is whether reports of allergic reaction to PVP1 solution warrant a similar pre-operative testing protocol, to avoid such complications.

## References

1. Chambers HF. Miscellaneous antimicrobial agents; disinfectants, antiseptics and sterilants. In: Basic and Clinical Pharmacology, 8th edition, Katzung B G(ed.): New York, NY, Lange Medical Books/McGraw-Hill,2001:852.
2. Brandao F M, Goossens A, Tosti A. Topical drugs. In: Textbook of Contact Dermatitis, 3rd edition, Rycroft R J G et al. (eds), Berlin, Springer, 2001:687-723.
3. Marks J G Jr, Elsner P, De Leon V. Contact and Occupational Dermatology, 3rd edition. St. Louis, Mosby, 2002.
4. Velázquez D, Zamberk P, Suárez R, Lázaro P. Allergic contact dermatitis to povidone-iodine. *Contact Dermatitis*. 2009;60:348-9.
5. Allergic contact dermatitis from povidone-iodine: a re-evaluation study. *Contact Dermatitis*. 2005;52:9-10.
6. Schreier H, Erdos G, Reimer, K et al. Molecular effects of povidone-iodine on relevant micro-organisms: an electron-microscopic and biochemical study. *Dermatology*. 1997;195Suppl:111-6.
7. Adachi A, Fukunaga A, Hayashi K, Kunisada M, Horikawa T. Anaphylaxis to polyvinylpyrrolidone after vaginal application of povidone-iodine. *Contact Dermatitis*. 2003;48:133-6.
8. Waran KD, Munsick RA. Anaphylaxis from povidone-iodine. *Lancet*. 1995; 345:1506.
9. Adachi A, Fukunaga A, Hayashi K et al. Anaphylaxis to polyvinylpyrrolidone after vaginal application of povidone-iodine. *Contact Dermatitis*. 2003;48:133-6.
10. Ancona A, Suarez de la Torre R, Macotella E. Allergic contact dermatitis from povidone-iodine. *Contact Dermatitis*. 1985;13:66-8.
11. Lopez Saez MP, de Barrio M, Zubeldia JH, Priet A, Olalde S, Baeza ML. Acute IgE-mediated generalized urticaria-angioedema after topical application of povidone-iodine. *Allergol Immunopathol*. 1998;26:23-6.
12. Rahimi S, Lazarou G. Late-onset allergic reaction to povidone-iodine resulting in vulvar edema and urinary retention. *Obstet Gynecol*. 2010;116:562-4.