

K. BORK<sup>1</sup>, M. DAVIS-LORTON<sup>2</sup>

# Overview of hereditary angioedema caused by C1-inhibitor deficiency: assessment and clinical management

<sup>1</sup>Department of Dermatology, Johannes Gutenberg University Mainz, Germany

<sup>2</sup>Department of Rheumatology, Allergy and Immunology, Winthrop University Hospital Mineola, New York, USA –  
E-mail: konrad.bork@unimedizin-mainz.de

## KEY WORDS

Angioedema, C1-inhibitor deficiency, hereditary angioedema (HAE), management

## Corresponding author

Konrad Bork, MD,  
Universitäts-Hautklinik, Langenbeckstr 1,  
55131 Mainz, Germany.  
Tel: 49-61-3117-7290;  
Fax: 49-61-3117-6614;  
E-mail: konrad.bork@unimedizin-mainz.de

## SUMMARY

Hereditary angioedema due to C1-inhibitor deficiency (HAE-C1-INH) is a rare, autosomal-dominant disease. HAE-C1-INH is characterized by recurrent attacks of marked, diffuse, nonpitting and nonpruritic skin swellings, painful abdominal attacks, and laryngeal edema. The extremities and the gastrointestinal tract are most commonly affected. Swelling of the upper respiratory mucosa poses the greatest risk because death from asphyxiation can result from laryngeal edema. HAE-C1-INH attacks are variable, unpredictable, and may be induced by a variety of stimuli, including stress or physical trauma. Because the clinical presentation of HAE-C1-INH is similar to other types of angioedema, the condition may be a challenge to diagnose. Accurate identification of HAE-C1-INH is critical in order to avoid asphyxiation by laryngeal edema and to improve the burden of disease. Based on an understanding of the underlying pathophysiology of HAE-C1-INH, drugs targeted specifically to the disease, such as C1-inhibitor therapy, bradykinin B2-receptor antagonists, and kallikrein-inhibitors, have become available for both treatment and prevention of angioedema attacks. This article reviews the clinical features, differential diagnosis, and current approaches to management of HAE-C1-INH.

## Introduction

Hereditary angioedema due to C1-inhibitor deficiency (HAE-C1-INH) is a rare genetic disorder that occurs in 1:10,000 to 1:50,000 people worldwide, with no known sex or race predominance (1). HAE-C1-INH manifests as abrupt, localized, transient, and often recurrent subcutaneous or submucosal edema, which can affect the face, extremities, genitals, abdomen, and upper respiratory tract (2,3). The majority of patients inherit the disease as an autosomal-dominant trait with a mutation in the C1-esterase inhibitor gene, but approximately 25% of cases are the result of *de novo* mutations (4,5). Two types of HAE-C1-INH occur; individuals with type I (about 85% of

cases) have a deficiency in functional C1 inhibitor, whereas type II (about 15% of cases) is characterized by dysfunctional C1 inhibitor. HAE-C1-INH typically begins in the first or second decade of life, with symptoms worsening during puberty and persisting throughout life in most patients. Although severity and frequency of HAE-C1-INH attacks may vary for each individual, past attacks do not predict severity of future attack or whether the airway may become involved.

Because HAE-C1-INH attacks are variable, unpredictable, and may affect numerous parts of the body, physicians from various specialties, including allergists, dermatologists, internists, gastroenterologists, and pediatricians, may encounter patients with HAE-C1-INH

who initially present with swelling or submucosal edema. Thus, it is important for clinicians to be familiar with the characteristics of HAE-C1-INH to make an accurate diagnosis. This article will review the clinical features, diagnosis, and current approaches to management of HAE-C1-INH.

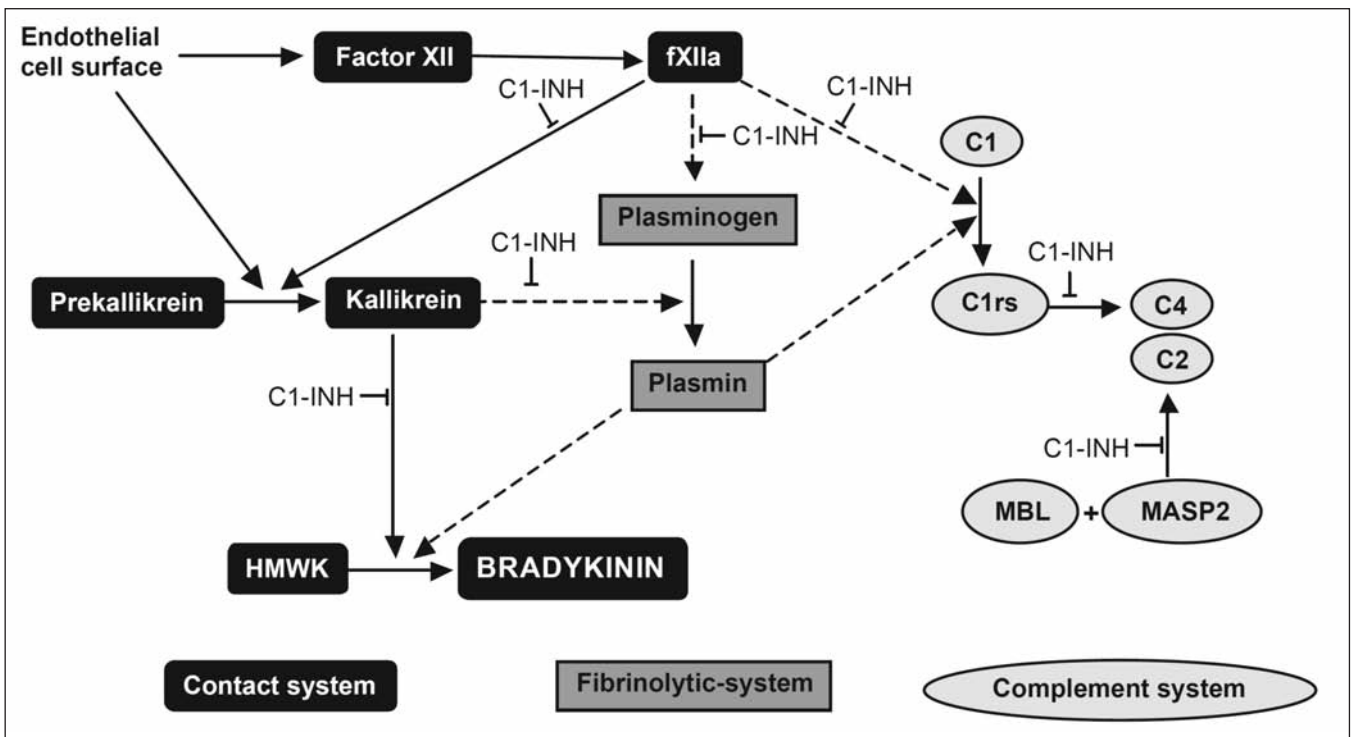
### Clinical features and consequences

HAE-C1-INH results as a consequence of mutations that occur in the C1-inhibitor gene located on chromosome 11, of which more than 200 mutations have been identified [6,7]. C1 inhibitor plays an important role in regulating the complement, contact, and fibrinolytic pathways (Figure 1) (8). C1-inhibitor also inhibits also thrombin and the coagulation system as demonstrated by in vitro studies [9] as well as clinical studies on patients with C1-inhibitor deficiency (10,11). When there is a quantitative or functional deficiency in C1 inhibitor, the result is unregulated release of bradykinin (12). The first demonstration of increased

levels of bradykinin during angioedema attacks in C1-inhibitor deficiency was made by Nussberger et al [13]; moreover, the generation of bradykinin was found to be increased in the site of the edema (14).

As C1 inhibitor is irreversibly consumed during an attack, the resultant overproduction of bradykinin leads to increased vascular permeability, extravasation, and edema. Some precipitating factors for attacks in patients with HAE-C1-INH include stress, physical trauma, infection, consumption of estrogen-containing or angiotensin-converting-enzyme-inhibitor-containing medications, and hormonal fluctuations (eg, during pregnancy or menstruation); however, swelling often occurs without an apparent trigger. HAE-C1-INH is characterized by episodic, localized, nonpitting and nonpruritic edema with ill-defined margins; heat and pain of varied severity may be experienced (15). Localized temporary swelling can affect the subcutaneous tissue of the skin, the gut wall in the gastrointestinal tract, or submucosal tissue in the upper respiratory system. Unlike urticaria, swelling from HAE-C1-INH affects tissues in deeper skin layers. Symptoms may be de-

**Figure 1** - The role of C1 inhibitor (C1-INH) in the contact, complement, and fibrinolytic system (adapted from reference 8, with permission). C1-INH = C1 inhibitor; fXIIa = activated coagulation factor XII; HMWK = high-molecular-weight kininogen; MBL = mannan-binding lectin; MASP2 = mannan-binding-lectin-associated protease 2.



scribed as more of a burning sensation rather than itching. Multiple areas of the body may be affected either simultaneously or consecutively. Many patients notice that attacks are preceded by a prodrome (eg, erythema marginatum, tingling sensation). Although sometimes occurring rapidly, swelling typically worsens gradually over the first 24 hours, may last from 1 to 5 days, and usually begins to resolve spontaneously over 48 to 72 hours (15,16). The extremities (ie, arms, hands, legs, feet) and the abdomen are most commonly affected. HAE-C1-INH attacks in the abdomen can cause significant pain, which often mimics acute abdominal emergencies (2). Swelling of the upper respiratory mucosa poses the greatest risk because laryngeal edema can lead to death from asphyxiation (17).

The consequences of undiagnosed and untreated HAE-C1-INH are significant. In the past, mortality rates of up to 30% have been reported as a result of asphyxiation, which can occur at any age with variable speed and degree of progression (18). Patients experiencing an abdominal attack of angioedema often have significant pain, circulatory disturbance, vomiting, and diarrhea (2), resulting at times in unnecessary surgical intervention (19-21). One study showed that misdiagnosed abdominal HAE-C1-INH resulted in unnecessary appendectomy or laparotomy in 35% of patients (22).

In the past, an accurate diagnosis of HAE-C1-INH was often not made upon initial presentation, which could lead to long periods of ineffective medical treatment and recurrent attacks (1,15,22). In an analysis of 313 patients with HAE-C1-INH, the average time to diagnosis after initial presentation of symptoms was 8.3 years, and patients reported visiting an average of 4.4 physicians before receiving an accurate diagnosis; allergic reactions and appendicitis were the most common misdiagnoses (22). Recurrent episodes of HAE-C1-INH have a significant negative impact on quality of life (23). Patients may be unable to work or go to school for as many as 20 to 100 days each year (24). In terms of reduced productivity and missed opportunities, participants with HAE-C1-INH in 1 survey reported a mean of 33.6% overall work impairment (a weighted combination of missed work and reduced productivity while at work), 48.4% felt their educational attainment was hindered, and nearly 70% felt they were unable to consider certain jobs because of their disease (23). Approximately 40% of these patients showed signs of depression. The frequent need for medical interventions to manage HAE-C1-INH can be costly, and management costs increase proportionally with disease severity (20).

## Differential diagnosis

HAE-C1-INH is often belatedly diagnosed because the disease is rare and the clinical symptoms of HAE-C1-INH may be difficult to distinguish from other forms of angioedema. No radiographic or endoscopic findings differentiate between various types of angioedema (25). Radiographs of angioedema occurring in the gastrointestinal tract typically show dilated loops of bowel, narrowing of the lumen, and ascites. Angioedema in the bowel or abdomen can occur in the absence of cutaneous manifestations and may be easily misdiagnosed unless the clinician has a high degree of awareness to include HAE-C1-INH in the differential diagnosis (2). Other conditions that manifest with angioedema should be ruled out in the differential diagnosis for HAE-C1-INH (26-28).

Acquired angioedema appears most similar to HAE-C1-INH, but is not associated with an underlying genetic defect (29). Like HAE-C1-INH, acquired angioedema primarily manifests as swelling in subcutaneous tissue, gastrointestinal mucosa, and upper respiratory tract mucosa. Unlike HAE-C1-INH, symptoms usually begin after the fourth decade of life in the absence of family history and are frequently associated with other disease states, such as malignancy, lymphoproliferative disorders, or autoimmune phenomena. The clinical course and prognosis for acquired angioedema are unpredictable. In some patients, successful treatment of the underlying disease leads to resolution of angioedema attacks, although this is not true for all patients (29).

Hereditary angioedema with normal C1 inhibitor (also referred to as HAE type III) has been described in numerous families. Some cases are associated with missense mutations or a deletion mutation in the coagulation factor XII gene (30,31). Hereditary angioedema with normal C1 inhibitor shows predominance in women (32,33).

Other forms of angioedema that may be considered in the differential diagnosis of HAE-C1-INH include angioedema caused by angiotensin-converting enzyme (ACE) inhibitors and idiopathic angioedema. IgE-mediated allergic reactions may also be a cause of transient angioedema, and a comprehensive history may elucidate a link between onset of swelling and exposure to an allergen (eg, food, medication, insect sting, latex). Angioedema may be associated with urticaria and can be treated with antihistamines or corticosteroids (28), which are ineffective for managing HAE-C1-INH. With nonsteroidal anti-inflammatory drugs (NSAIDs), the reaction often occurs within minutes of drug administration (27), whereas approximately 50% of

ACE inhibitor-induced angioedema occurs within the first week of treatment (34). The onset of angioedema symptoms may also occur after several months to years of treatment with ACE-inhibitors (35). Pruritus and urticaria rarely occur with angioedema secondary to ACE-inhibitor therapy (36). Patients with idiopathic angioedema experience episodes of recurrent swelling with no apparent cause; fever and leukocytosis are unusual. Following careful systematic assessment to rule out other known causes of angioedema, the diagnosis of idiopathic recurrent angioedema is based on meeting the definition of chronic, recurrent angioedema without an identifiable cause after comprehensive medical evaluation.

### **Diagnosing hereditary angioedema due to C1-inhibitor deficiency**

In every case of recurrent angioedema without urticaria, HAE-C1-INH should be considered, particularly in individuals with a positive family history. Accurate diagnosis of HAE-C1-INH is guided by laboratory analysis of circulating complement components (Figure 2) (1). Measurement of complement functional and quantitative C1 inhibitor and C4 is recommended. During an attack of angioedema, the concentration of C4 is markedly diminished and may be undetectable in patients with HAE-C1-INH. Measurement of antigenic and functional C1-inhibitor levels differentiate between type I (low antigenic and functional C1-inhibitor levels) and type II (normal antigenic C1 inhibitor with low functional C1-inhibitor levels). Types I and II HAE-C1-INH may be ruled out if C1-inhibitor functional assays and C4 antigenic protein are both normal (1).

### **Treatment options for hereditary angioedema due to c1-inhibitor deficiency**

Unlike angioedema induced by allergens or medications, which may be treated by removing the causative agent, HAE-C1-INH requires life-long monitoring and management in many cases. Management of HAE-C1-INH can be categorized into 1) acute treatment for attacks, with a focus on quickly alleviating the progression and severity of attacks, and 2) prophylaxis to avoid attacks or to reduce incidence of attacks. Pain management and supportive care should be provided during acute attacks, particularly in patients suffering from an abdominal episode.

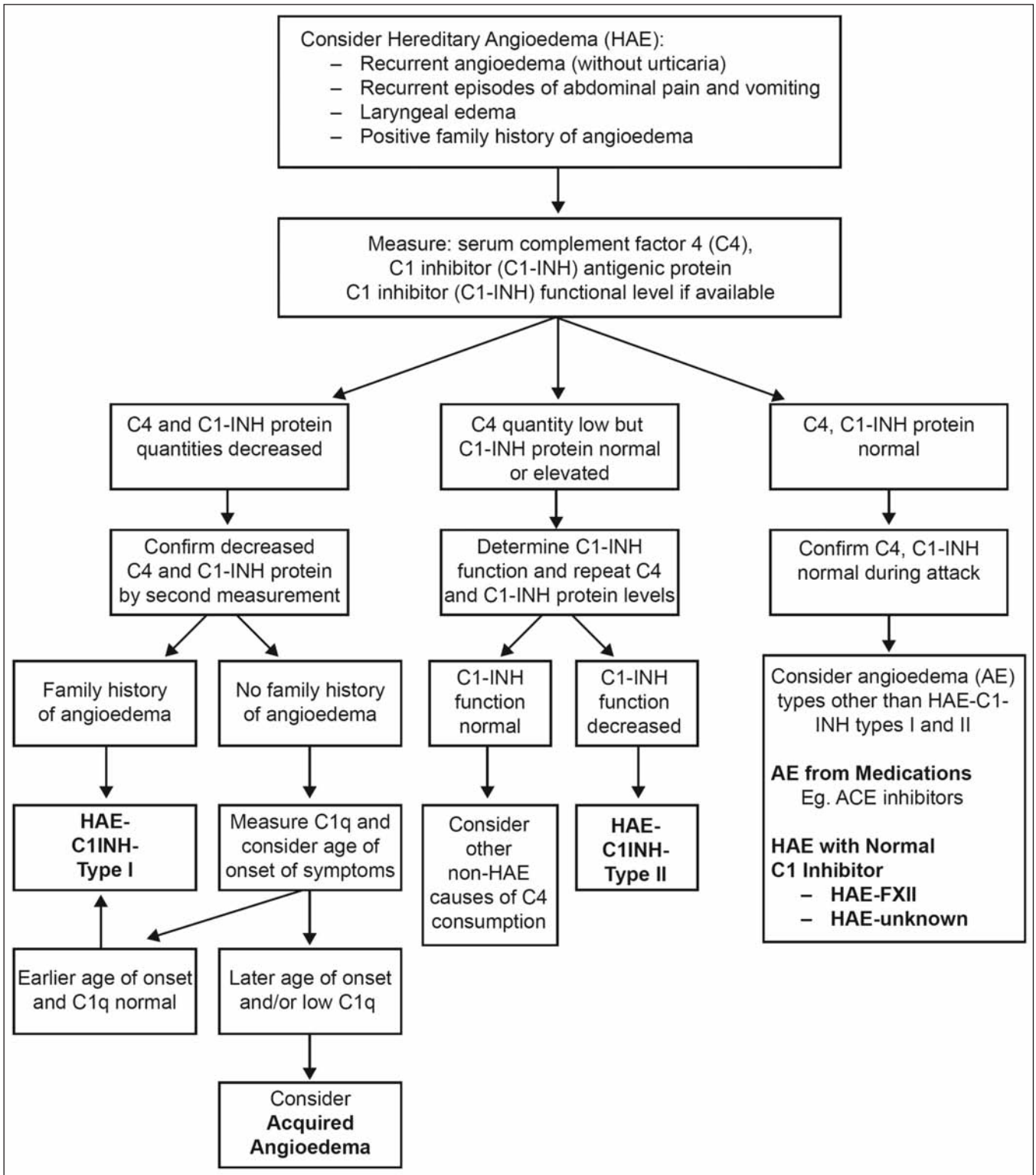
Additionally, maintenance of the airway is critical, and intubation should be considered early in progressive laryngeal edema.

#### *Treatment for Acute Attacks*

Angioedema in patients with HAE-C1-INH does not respond to antihistamines, corticosteroids, or epinephrine. Historically, management of HAE-C1-INH was limited to alleviating clinical symptoms (eg, fluid replacement, pain management). Solvent detergent or fresh frozen plasma was utilized as a source of C1 inhibitor. Although fresh frozen plasma remains an option when other therapies are unavailable and has been used successfully in pregnant women with HAE-C1-INH and in the emergency department (4,37,38), clinical efficacy data are limited, and plasma contains substrates that could theoretically worsen symptoms in patients with HAE-C1-INH (1). Currently, several clinically effective options for treating HAE-C1-INH attacks are available, including C1-inhibitor replacement and agents that affect specific points in the contact system, such as the bradykinin B2-receptor antagonist (icatibant) and the kallikrein-inhibitor (ecallantide) (Table 1) (15,39).

C1-inhibitor replacement (human or recombinant) is a safe and effective disease-targeted treatment that is an excellent option for HAE-C1-INH attacks, including life-threatening laryngeal edema and use during pregnancy (1,40-45). In most patients, symptoms begin to improve within 15 to 60 minutes of C1-inhibitor administration (46-50). Numerous case studies and clinical trials have demonstrated the safety and efficacy of pasteurized C1 inhibitor (41,46,48,51,52). In a retrospective analysis, treatment with pasteurized C1 inhibitor (500 U) consistently relieved severe abdominal, subcutaneous, and laryngeal edema in patients with HAE-C1-INH, with no recurrence within 72 hours of the attack (47). In 16 patients who experienced 39 laryngeal attacks, open-label treatment with a single dose of pasteurized C1 inhibitor (20 U/kg) relieved laryngeal edema within a median time of 15 minutes, with complete resolution of symptoms by 8 hours (42). A prospective, open-label study evaluating pasteurized C1-inhibitor concentrate (20 U/kg) in treatment of successive acute abdominal and facial HAE-C1-INH attacks in 50 patients showed that median time to onset of relief for all attacks was 19.8 minutes, with complete resolution occurring at a median of 11 hours (48). A double-blind, placebo-controlled study showed that median time to onset of symptom relief was significantly shorter with pasteurized C1 inhibitor (20 U/kg) compared with placebo (0.5 vs

**Figure 2** - Hereditary and acquired forms of angioedema: Diagnostic algorithm (1). AE = angioedema; ACE = angiotensin-converting enzyme.



**Table 1** - General measures for treatment of acute attacks of hereditary angioedema due to C1-inhibitor deficiency (HAE-C1-INH), in the order of historical availability and experience in Europe

Treat as early as possible during an attack

1. Dosages (adults):

- a. Pasteurized C1 inhibitor (marketed as Berinert®; CSL Behring, Marburg, Germany) 20 U/kg IV
- b. Icatibant (marketed as Firazyr®; Shire Orphan Therapies, Lexington, MA, USA) 30 mg SC
- c. Nanofiltered C1 inhibitor (marketed as Cinryze®; ViroPharma Biologics, Inc, Exton, PA, USA) 1000 U IV; second 1000 U if no response within 60 minutes
- d. Recombinant C1 inhibitor (marketed as Ruconest®; Pharming Group NV, Leiden, Netherlands) 50 U/kg IV; 4200 U IV in adults >84 kg
- e. Ecallantide (marketed as Kalbitor®; Dyax Corp, Cambridge, MA, USA) 30 mg SC split into 3 injections (not available in Europe)

2. If first-line agent not available, consider solvent detergent-treated plasma (SDP) or fresh frozen plasma

3. Intubation: consider early in progressive laryngeal edema

*IV* = intravenous; *SC* = subcutaneous.

1.5 hours;  $P=.0025$ ) in 125 patients with HAE-C1-INH (51). The most frequently reported adverse events with pasteurized C1 inhibitor in this study were nausea, diarrhea, abdominal pain, and muscle spasms.

In June 2011, a nanofiltered C1 inhibitor was approved in Europe for acute attacks of HAE-C1-INH. In a double-blind, placebo-controlled trial, nanofiltered C1 inhibitor was evaluated for treatment of acute attacks of angioedema in 68 subjects with HAE-C1-INH (49). Patients were randomly assigned to receive either nanofiltered C1 inhibitor (1000 U/dose; up to 2 doses;  $N=35$ ) or placebo ( $N=33$ ). Median time to onset of unequivocal relief from the attack was reduced by half in the nanofiltered C1-inhibitor group compared with the group receiving placebo (2 vs 4 hours, respectively;  $P=.02$ ). Median time to complete resolution of symptoms was 12.3 hours in the nanofiltered C1-inhibitor group compared with 25 hours in the placebo group ( $P=.004$ ). Efficacy was further confirmed in an open-label, multicenter study that evaluated the efficacy and safety of nanofiltered C1 inhibitor 1000 U administered for the treatment of 609 attacks in 113 patients with HAE-C1-INH (53). Within 4 hours of treatment, 87% of patients achieved unequivocal relief and 95.5% achieved clinical relief (defined in the study as patients with either unequivocal relief *or* 1 or 2 consecutive assessments consistent with improvement followed by cessation of symptom assessments).

Furthermore, a recombinant C1 inhibitor is available. In 2 randomized, double-blind trials, patients with HAE-C1-INH were randomized to a single intravenous infusion of recombinant C1 inhibitor at a dose of 100 U/kg ( $N=29$ ) or 50 U/kg ( $N=12$ ), or placebo ( $N=29$ ) (50). The primary end

point, beginning of relief of symptoms, was achieved at a median of 66 minutes in the 100-U/kg group ( $P<.001$ ), 122 minutes in the 50-U/kg group ( $P=.013$ ), and 495 minutes in the placebo group. Median time to minimal symptoms was also significantly reduced in the recombinant C1-inhibitor groups (266 minutes in the 100-U/kg group [ $P<.001$ ] and 247 minutes in the 50-U/kg group [ $P=.013$ ]) compared with the placebo group (1210 minutes).

Targeted therapies for HAE-C1-INH that act at specific points in the contact system include a selective competitive bradykinin B2-receptor antagonist (icatibant) and a recombinant plasma kallikrein inhibitor (ecallantide) (54-56). Icatibant is effective for the acute management of HAE-C1-INH (54). In the double-blind For Angioedema Subcutaneous Treatment (FAST)-1 trial, patients with HAE-C1-INH who presented with cutaneous or abdominal attacks were randomized to either icatibant 30 mg subcutaneous ( $N=27$ ) or placebo ( $N=29$ ); in FAST-2, patients were randomly assigned to either icatibant 30 mg subcutaneous ( $N=36$ ) or oral tranexamic acid 3 g daily for 2 days ( $N=38$ ). The primary end point, median time to clinically significant relief of symptoms, was reached in 2.5 hours in the icatibant group versus 4.6 hours with placebo ( $P=.14$ ) in FAST-1, and in 2.0 hours in the icatibant group compared with 12 hours in the tranexamic acid group ( $P<.001$ ) in FAST-2. The most common adverse events with icatibant were recurrent or worsening angioedema and injection-site reactions. In a double-blind, placebo-controlled trial, treatment with ecallantide 30 mg subcutaneous ( $N=36$ ) was compared with placebo ( $N=36$ ) in patients with HAE-C1-INH who presented during an attack (55). Four hours after treatment, patient-

reported treatment outcome scores ( $P=.004$ ) and mean symptoms complex severity scores ( $P=.01$ ) were significantly better in the ecallantide group compared with the placebo group. Headache, diarrhea, pyrexia, and nasal congestion were reported more often with ecallantide than with placebo. Of note, anaphylaxis has been reported following administration of ecallantide, therefore, patients should be carefully monitored when utilizing this agent. In clinical trials, 2.7% of patients with HAE-C1-INH who were treated with subcutaneous ecallantide experienced anaphylaxis, which typically occurred within the first hour after dosing (57).

### Prophylaxis

For patients with HAE-C1-INH, number of attacks per year does not predict severity of the next attack or whether a future attack will involve the airway; thus, risk of asphyxiation remains a possibility regardless of past history (17). Routine prophylaxis should be considered for patients with HAE-C1-INH who have 1 or more severe attacks per month or if treatment for acute attacks is ineffective or unavailable (1). Routine prophylaxis is also appropriate for patients who do not achieve adequate benefit from on-demand therapy. Ultimately, the decision to use prophylactic treatment should be individualized through close collaboration between the patient and clinician, with the goal of helping patients maintain good quality of life. Prophylactic therapies for HAE-C1-INH include attenuated androgens, C1 inhibitor, and antifibrinolytics (Table 2) (15,39). In patients with HAE-C1-INH, it is also important to avoid conditions facilitating or triggering attacks, such as use of ACE inhibitor therapy or hormonal contraceptives.

Androgens have been used successfully for prophylaxis of HAE-C1-INH for more than 50 years and are the most fre-

quently prescribed therapy in many countries (58,59). Although the exact mechanism of attenuated androgens in treating HAE is unknown, these agents are thought to increase endogenous C1-inhibitor levels by hepatic synthesis and increased expression of mRNA. Danazol, stanozolol, and oxandrolone are employed most commonly in HAE-C1-INH. The efficacy of danazol 200 mg three times daily in preventing attacks of HAE-C1-INH was established in a double-blind, placebo-controlled trial in 1976 (58). At present, considerably lower doses are recommended to minimize dose-dependent adverse effects. In a retrospective analysis of 118 patients with HAE-C1-INH who were treated with long-term danazol therapy (mean dosage was 171.2 mg/d; range, 40-1000 mg/d), nearly 50% of patients became completely or practically symptom free ( $\leq 1$  attack per year), attack frequency was reduced to 16.2%, and attacks were considerably milder than before treatment (60). However, 6% of patients did not respond to danazol therapy, and 1 or more adverse effects occurred in 78.8% (93/118) of patients and led to discontinuation of therapy in 30 patients (25.4%). Once symptom control is established with androgen therapy, doses should be titrated to the lowest effective amount to minimize adverse effects (1). Potential adverse effects of androgen therapy include weight gain, menstrual irregularities, arterial hypertension, virilization, behavioral issues, and lipid abnormalities (60-62); a few cases with hepatic adenomas have been reported (63). Androgens are not recommended for use in children and pregnant women.

Several clinical trials support the effectiveness of long-term C1-inhibitor prophylaxis for HAE-C1-INH (49,64,65). Prophylactic twice-weekly injections of nanofiltered C1 inhibitor (1000 U) were compared with placebo during two 12-week periods in a randomized, crossover trial involving 22 patients with HAE-C1-INH (49). Number of attacks during the 12-week period was reduced by 50% with

**Table 2** - Therapy options for routine prophylaxis of hereditary angioedema due to C1-inhibitor deficiency (HAE-C1-INH) in adults

1.  $17\alpha$ -Alkylated androgens
  - a. Danazol (marketed as Danocrine®; Sanofi-Synthelabo, New York, NY, USA) 100 mg PO every 3 days to 200 mg QD
  - b. Oxandrolone (marketed as Oxandrin®; Savient Pharmaceuticals, Inc, East New Brunswick, NJ, USA) 2.5 mg PO every 3 days to 20 mg QD
  - c. Stanozolol (marketed as Winstrol®; Sanofi-Aventis) 1 mg PO every 3 days to 6 mg QD
2. C1 inhibitor
  - a. Nanofiltered C1 inhibitor (marketed as Cinryze®; ViroPharma Biologics, Inc, Exton, PA, USA) 1000 U IV every 3 or 4 days
3. Antifibrinolytic agent
  - a. Tranexamic acid (marketed as Cyklokapron®; Pfizer, New York, NY, USA) 20-50 mg/kg/day PO split BID or TID

*BID = twice daily; IV = intravenous; PO = by mouth; QD = daily; TID = three times daily.*

nanofiltered C1-inhibitor prophylaxis (6.26;  $P < .001$ ) compared with placebo (12.73). Prophylactic treatment with nanofiltered C1 inhibitor also reduced the severity and duration of attacks, the need for open-label rescue medication, and total number of days with swelling. In the open-label extension of this trial, 146 patients with HAE-C1-INH received nanofiltered C1 inhibitor administered prophylactically at 1000 U every 3 to 7 days (65). Prior to enrollment, patients reported a median attack rate of 3.0 per month, which was reduced to 0.2 per month while receiving prophylactic therapy; 86% of patients experienced an average of 1 or fewer attacks per month and 35% reported no attacks during the study. The vast majority of patients treated prophylactically with nanofiltered C1 inhibitor tolerated the medication without adverse effects (49,65).

A prospective observational trial evaluated long-term treatment with 1 or more weekly injections of pasteurized C1 inhibitor (dose ranged from 500-7000 U) for an average of 9 years in 19 patients with HAE-C1-INH (64). Patients reported that all or most attacks were less severe on prophylactic therapy, and the percentages of severe attacks were 93.3% without treatment and 3.8% with pasteurized C1-inhibitor prophylaxis. However, in some patients the number of attacks increased considerably, and a few patients needed continuously more C1 inhibitor to control attacks. Furthermore, a more rapid progression of attacks and the occurrence of multilobular attacks were reported. Properly trained patients may keep a supply of C1 inhibitor to facilitate prophylactic therapy when indicated or for self-administration (1,39,66,67).

Antifibrinolytic agents (tranexamic acid,  $\epsilon$ -aminocaproic acid) inhibit formation and activity of plasmin, subsequently decreasing plasmin-induced activation of C1. These agents are less effective than attenuated androgens in decreasing number and severity of attacks, but provide an option for routine prophylaxis in children (1,66,68,69) or in patients who are unresponsive or intolerant of androgens or intravenous therapy. Common adverse effects associated with antifibrinolytics include nausea, vertigo, diarrhea, postural hypertension, fatigue, and myalgia.

The primary goal of pre-procedural prophylaxis is prevention of an HAE-C1-INH attack that may be triggered by a medical, surgical, or dental procedure. International guidelines recommend C1-inhibitor therapy administered 1 to 6 hours prior to major procedures or intubation (1,66). A systematic evaluation of 171 patients with HAE-C1-INH who were at risk for an attack following tooth extractions showed that facial swelling, potentially life-threatening edema, or both occurred in 21.5%

(124/577) of extractions in patients who did not receive prophylaxis compared with 12.5% (16/128) of extractions in the patients who received pre-procedural C1-inhibitor prophylaxis (70). Although a few cases of laryngeal edema and facial swellings were reported after tooth extraction despite prophylaxis in this study, the overall incidence of swelling was markedly reduced with pre-procedural prophylaxis. If C1-inhibitor therapy is immediately available, pre-procedural prophylaxis may not be needed for minor manipulations (1). If C1 inhibitor is unavailable, attenuated androgens given for 5 days before and 2 to 5 days after the procedure may be used (1,66). Solvent-treated or fresh frozen plasma administered 1 to 6 hours before the procedure has also been tried (1,45).

## Conclusions

HAE-C1-INH is a rare, genetic disorder characterized by recurrent attacks of subcutaneous edema affecting various parts of the body. Improper diagnosis of HAE-C1-INH can result in unnecessary treatments, including surgery, delay in administration of appropriate therapy, recurrent attacks, and significant disease burden for patients. Therefore, any patient who presents with repeated episodes of swelling should be evaluated for HAE-C1-INH. The importance of accurate diagnosis of HAE-C1-INH is paramount in order to determine the most effective treatment options. Several disease-targeted therapies are available for treatment of acute attacks and routine and pre-procedural prophylaxis in patients with HAE-C1-INH.

## Acknowledgments

Scientific Therapeutics Information, Inc (Madison Springfield, New Jersey) provided editorial assistance on this manuscript. Funding for editorial assistance was provided by ViroPharma Incorporated.

**Disclosures:** K. Bork, consultant, CSL Behring, Shire, ViroPharma; M. Davis-Lorton, fee for manuscript preparation, ViroPharma; grant to my institution, ViroPharma; speakers' bureau, ViroPharma

**Funding/Support:** Scientific Therapeutics Information, Inc (Springfield, New Jersey) provided editorial assistance on this manuscript. Funding for editorial assistance was provided by ViroPharma Incorporated.



## References

- Bowen T, Cicardi M, Farkas H, et al. 2010 International consensus algorithm for the diagnosis, therapy and management of hereditary angioedema. *Allergy Asthma Clin Immunol* 2010; 6: 24.
- Bork L, Staubach P, Eckardt AJ, Hardt J. Symptoms, course, and complications of abdominal attacks of hereditary angioedema due to C1 inhibitor deficiency. *Am J Gastroenterol* 2006; 101: 619-27.
- Bork K, Meng G, Staubach P, Hardt J. Hereditary angioedema: new findings concerning symptoms, affected organs, and course. *Am J Med* 2006; 119: 267-74.
- Nzeako UC, Frigas E, Tremaine WJ. Hereditary angioedema: a broad review for clinicians. *Arch Intern Med* 2001; 161: 2417-29.
- Pappalardo E, Cicardi M, Duponchel C, et al. Frequent de novo mutations and exon deletions in the C1inhibitor gene of patients with angioedema. *J Allergy Clin Immunol* 2000; 106: 1147-54.
- Cugno M, Zanichelli A, Foini F, Caccia S, Cicardi M. C1-inhibitor deficiency and angioedema: molecular mechanisms and clinical progress. *Trends Mol Med* 2009; 15: 69-78.
- Kalmár L, Hegedüs T, Farkas H, Nagy M, Tordai A. HAEdb: a novel interactive, locus-specific mutation database for the C1 inhibitor gene. *Hum Mutat* 2005; 25: 1-5.
- Bork K. Recurrent angioedema and the threat of asphyxiation. *Dtsch Arztebl Int* 2010; 107: 408-14.
- Caccia S, Castelli R, Maiocchi D, Bergamaschini L, Cugno M. Interaction of C1 inhibitor with thrombin on the endothelial surface. *Blood Coagul Fibrinolysis* 2011; 22: 571-5.
- Cugno M, Zanichelli A, Bellatorre AG, Griffini S, Cicardi M. Plasma biomarkers of acute attacks in patients with angioedema due to C1-inhibitor deficiency. *Allergy* 2009; 64: 254-7.
- van Geffen M, Cugno M, Lap P, Loof A, Cicardi M, van Heerde W. Alterations of coagulation and fibrinolysis in patients with angioedema due to C1-inhibitor deficiency. *Clin Exp Immunol* 2012; 167: 472-8.
- Davis AE III. The pathophysiology of hereditary angioedema. *Clin Immunol* 2005; 114: 3-9.
- Nussberger J, Cugno M, Amstutz C, Cicardi M, Pallacani A, Agostoni A. Plasma bradykinin in angio-oedema. *Lancet* 1998; 351: 1693-7.
- Nussberger J, Cugno M, Cicardi M, Agostoni A. Local bradykinin generation in hereditary angioedema. *J Allergy Clin Immunol* 1999; 104: 1321-2.
- Zuraw BL. Hereditary angioedema. *N Engl J Med* 2008; 359: 1027-36.
- Kemp JG, Craig TJ. Variability of prodromal signs and symptoms associated with hereditary angioedema attacks: a literature review. *Allergy Asthma Proc* 2009; 30: 493-9.
- Bork K, Siedlecki K, Bosch S, Schopf RE, Kreuz W. Asphyxiation by laryngeal edema in patients with hereditary angioedema. *Mayo Clin Proc* 2000; 75: 349-54.
- Agostoni A, Aygören-Pürsün E, Binkley KE, et al. Hereditary and acquired angioedema: problems and progress. Proceedings of the third C1 esterase inhibitor deficiency workshop and beyond. *J Allergy Clin Immunol* 2004; 114(3 suppl): S51-131.
- Agostoni A, Cicardi M. Hereditary and acquired C1-inhibitor deficiency: biological and clinical characteristics in 235 patients. *Medicine (Baltimore)* 1992; 71: 206-15.
- Wilson DA, Bork K, Shea EP, Rentz AM, Blaustein MB, Pullman WE. Economic costs associated with acute attacks and long-term management of hereditary angioedema. *Ann Allergy Asthma Immunol* 2010; 104: 314-20.
- Zilberberg M, Jacobsen T, Tillotson G. The burden of hospitalizations and emergency department visits with hereditary angioedema and angioedema in the United States, 2007. *Allergy Asthma Proc* 2010; 31: 511-9.
- Lunn ML, Santos CB, Craig TJ. Is there a need for clinical guidelines in the United States for the diagnosis of hereditary angioedema and the screening of family members of affected patients? *Ann Allergy Asthma Immunol* 2010; 104: 211-4.
- Lumry WR, Castaldo AJ, Vernon MK, Blaustein MB, Wilson DA, Horn PT. The humanistic burden of hereditary angioedema: impact on health-related quality of life, productivity, and depression. *Allergy Asthma Proc* 2010; 31: 407-14.
- Cicardi M, Agostoni A. Hereditary angioedema [editorial]. *N Engl J Med* 1996; 334: 1666-7.
- Frigas E, Park M. Idiopathic recurrent angioedema. *Immunol Allergy Clin North Am* 2006; 26: 739-51.
- Nzeako UC. Diagnosis and management of angioedema with abdominal involvement: a gastroenterology perspective. *World J Gastroenterol* 2010; 16: 4913-21.
- Kaplan AP, Greaves MW. Angioedema. *J Am Acad Dermatol* 2005; 53: 373-88.
- Weldon D. Differential diagnosis of angioedema. *Immunol Allergy Clin North Am* 2006; 26: 603-13.
- Zingale LC, Castelli R, Zanichelli A, Cicardi M. Acquired deficiency of the inhibitor of the first complement component: presentation, diagnosis, course, and conventional management. *Immunol Allergy Clin North Am* 2006; 26: 669-90.
- Bork K, Wulff K, Meinke P, Wagner N, Hardt J, Witzke G. A novel mutation in the coagulation factor 12 gene in subjects with hereditary angioedema and normal C1-inhibitor. *Clin Immunol* 2011; 141(1): 31-5.
- Dewald G, Bork K. Missense mutations in the coagulation factor XII (Hageman factor) gene in hereditary angioedema with normal C1 inhibitor. *Biochem Biophys Res Comm* 2006; 343: 1286-9.
- Bork K. Hereditary angioedema with normal C1 inhibitor activity including hereditary angioedema with coagulation factor XII gene mutations. *Immunol Allergy Clin North Am* 2006; 26: 709-24.
- Bork K, Gül D, Hardt J, Dewald G. Hereditary angioedema with normal C1 inhibitor: clinical symptoms and course. *Am J Med* 2007; 120: 987-92.
- Sabroe RA, Black AK. Angiotensin-converting enzyme (ACE) inhibitors and angio-oedema. *Br J Dermatol* 1997; 136: 153-8.
- Agostoni A, Cicardi M, Cugno M, Zingale LC, Gioffre D, Nussberger J. Angioedema due to angiotensin-converting enzyme inhibitors. *Immunopharmacology* 1999; 15: 21-5.
- Malde B, Regalado J, Greenberger PA. Investigation of angioedema associated with the use of angiotensin-converting enzyme inhibitors and angiotensin receptor blockers. *Ann Allergy Asthma Immunol* 2007; 98: 57-63.
- McGlinchey PG, Golchin K, McCluskey DR. Life-threatening laryngeal oedema in a pregnant woman with hereditary angioedema. *Ulster Med J* 2000; 69: 54-7.
- Prematta M, Gibbs JG, Pratt EL, Stoughton TR, Craig TJ. Fresh frozen plasma for the treatment of hereditary angioedema. *Ann Allergy Asthma Immunol* 2007; 98: 383-8.
- Cicardi M, Bork K, Caballero T, et al, on behalf of the HAWK (Hereditary Angioedema International Working Group). Evi-

- dence-based recommendations for the therapeutic management of angioedema owing to hereditary C1 inhibitor deficiency: consensus report of an International Working Group. *Allergy* 2012; 67: 147-57.
40. Baker J, Riedl M, Banerji A, et al. Open-label use of nanofiltered C1 esterase inhibitor (human) (Cinryze) for treatment or prophylaxis of acute attacks of hereditary angioedema (HAE) in pregnant subjects [abstract]. *Ann Allergy Asthma Immunol* 2010; 105: A10.
  41. Bork K. Human pasteurized C1-inhibitor concentrate for the treatment of hereditary angioedema due to C1-inhibitor deficiency. *Expert Review Clin Immunol* 2011; 7(6): 723-33.
  42. Craig TJ, Wasserman RL, Levy RJ. Prospective study of rapid relief provided by C1 esterase inhibitor in emergency treatment of acute laryngeal attacks in hereditary angioedema. *J Clin Immunol* 2010; 30: 823-9.
  43. Czaller I, Visy B, Csuka D, Füst G, Tóth F, Farkas H. The natural history of hereditary angioedema and the impact of treatment with human C1-inhibitor concentrate during pregnancy: a long-term survey. *Eur J Obstet Gynecol Reprod Biol* 2010; 152: 44-9.
  44. Martinez-Saguer I, Rusicke E, Aygören-Pürsün E, Heller C, Klingebiel T, Kreuz W. Characterization of acute hereditary angioedema attacks during pregnancy and breast-feeding and their treatment with C1 inhibitor concentrate. *Am J Obstet Gynecol* 2010; 203: 131.e1-7.
  45. Zuraw BL. Hereditary angioedema: a current state-of-the-art review, IV: short- and long-term treatment of hereditary angioedema: out with the old and in with the new? *Ann Allergy Asthma Immunol* 2008; 100(1 suppl 2): S13-8.
  46. Bork K, Staubach P, Hardt J. Treatment of skin swellings with C1-inhibitor concentrate in patients with hereditary angio-oedema. *Allergy* 2008; 63: 751-7.
  47. Farkas H, Jakab L, Temesszentandrási G, et al. Hereditary angioedema: a decade of human C1-inhibitor concentrate therapy. *J Allergy Clin Immunol* 2007; 120: 941-7.
  48. Wasserman RL, Levy RJ, Bewtra AK, et al. Prospective study of C1 esterase inhibitor in the treatment of successive acute abdominal and facial hereditary angioedema attacks. *Ann Allergy Asthma Immunol* 2011; 106: 62-8.
  49. Zuraw BL, Busse PJ, White M, et al. Nanofiltered C1 inhibitor concentrate for treatment of hereditary angioedema. *N Engl J Med* 2010; 363: 513-22.
  50. Zuraw B, Cicardi M, Levy RJ, et al. Recombinant human C1-inhibitor for the treatment of acute angioedema attacks in patients with hereditary angioedema. *J Allergy Clin Immunol* 2010; 126: 821-7.
  51. Craig TJ, Levy RJ, Wasserman RL, et al. Efficacy of human C1 esterase inhibitor concentrate compared with placebo in acute hereditary angioedema attacks. *J Allergy Clin Immunol* 2009; 124: 801-8.
  52. De Seres J, Gröner A, Lindner J. Safety and efficacy of pasteurized C1 inhibitor concentrate (Berinert P) in hereditary angioedema: a review. *Transfus Apher Sci* 2003; 29: 247-54.
  53. Riedl MA, Hurewitz DS, Levy R, Busse PJ, Fitts D, Kalfus I. Nanofiltered C1 esterase inhibitor (human) for treatment of acute attacks of hereditary angioedema: an open-label trial. *Ann Allergy Asthma Immunol* 2012; 108: 49-53.
  54. Cicardi M, Banerji A, Bracho F, et al. Icatibant, a new bradykinin-receptor antagonist, in hereditary angioedema. *N Engl J Med* 2010; 363: 532-41.
  55. Cicardi M, Levy RJ, McNeil DL, et al. Ecallantide for the treatment of acute attacks in hereditary angioedema. *N Engl J Med* 2010; 363: 523-31.
  56. Krause K, Metz M, Zuberbier T, Maurer M, Magerl M. Successful treatment of hereditary angioedema with bradykinin B2-receptor antagonist icatibant. *J Dtsch Dermatol Ges* 2010; 8: 272-4.
  57. Kalbitor (ecallantide) prescribing information. Dyax Corporation, Cambridge, MA; February 2012. <http://kalbitor.com/hcp/rems/pdf/KalbitorFullPrescribingInformation.pdf> Accessed May 15, 2012.
  58. Gelfand JA, Sherins RJ, Alling DW, Frank MM. Treatment of hereditary angioedema with danazol. Reversal of clinical and biochemical abnormalities. *N Engl J Med* 1976; 295: 1444-8.
  59. Spaulding WB. Methyltestosterone therapy for hereditary episodic edema (hereditary angioneurotic edema). *Ann Intern Med* 1960; 53: 739-45.
  60. Bork K, Bygum A, Hardt J. Benefits and risks of danazol in hereditary angioedema: a long-term survey of 118 patients. *Ann Allergy Asthma Immunol* 2008; 100: 153-61.
  61. Cicardi M, Castelli R, Zingale LC, Agostoni A. Side effects of long-term prophylaxis with attenuated androgens in hereditary angioedema: comparison of treated and untreated patients. *J Allergy Clin Immunol* 1997; 99: 194-6.
  62. Zurlo JJ, Frank MM. The long-term safety of danazol in women with hereditary angioedema. *Fertil Steril* 1990; 54: 64-72.
  63. Bork K, Pitton M, Harten P, Koch P. Hepatocellular adenomas in patients taking danazol for hereditary angio-oedema. *Lancet* 1999; 353(9158): 1066-7.
  64. Bork K, Hardt J. Hereditary angioedema: long-term treatment with one or more injections of C1 inhibitor concentrate per week. *Int Arch Allergy Immunol* 2011; 154: 81-8.
  65. Zuraw BL, Kalfus I. Safety and efficacy of prophylactic nanofiltered C<sub>1</sub>-inhibitor in hereditary angioedema. *Am J Med* 2012; 125: 938. e1-7.
  66. Gompels MM, Lock RJ, Abinun M, et al. C1 inhibitor deficiency: consensus document. *Clin Exp Immunol* 2005; 139: 379-94.
  67. Kreuz W, Rusicke E, Martinez-Saguer I, Aygören-Pürsün E, Heller C, Klingebiel T. Home therapy with intravenous human C1-inhibitor in children and adolescents with hereditary angioedema. *Transfusion* 2011; 52: 100-7.
  68. Boyle RJ, Nikpour M, Tang MLK. Hereditary angio-oedema in children: a management guideline. *Pediatr Allergy Immunol* 2005; 16: 288-94.
  69. Farkas H. Pediatric hereditary angioedema due to C1-inhibitor deficiency. *Allergy Asthma Clin Immunol* 2010; 6: 18.
  70. Bork K, Hardt J, Staubach-Renz P, Witzke G. Risk of laryngeal edema and facial swellings after tooth extraction in patients with hereditary angioedema with and without prophylaxis with C1 inhibitor concentrate: a retrospective study. *Oral Surg Oral Med Oral Pathol Oral Radiol Endodont* 2011; 112(1): 58-64.