

F. CODREANU, S. JARLOT, C. ASTIER, M. TISSERAND, Z. ASBATI, R. HATAHET,
P. SERGEANT, G. KANNY

An apple a day...chronic glossitis in a 4-year-old boy

EA 3999 "Allergy Diseases: Diagnosis & Therapeutics", Department of Internal Medicine, Clinical Immunology and Allergology, University Hospital of Nancy, Nancy, France - E-mail: g.kanny@chu_nancy.fr

KEY WORDS

Food allergy, glossitis, scurvy

Corresponding author

Gisèle Kanny
EA 3999 "Allergy Diseases:
Diagnosis & Therapeutics",
Department of Internal Medicine,
Clinical Immunology and
Allergology, University Hospital of
Nancy, Nancy, France
E-mail: g.kanny@chu_nancy.fr

SUMMARY

We report a case of chronic glossitis in a 4-year-old boy due to scurvy. The boy showed up in our department with a patchy depapillated tongue. A detailed dietary history revealed an unbalanced diet without any fruit or vegetable. The biological investigations showed a low serum ascorbic acid. The boy was treated by oral ascorbic acid during 15 days. The glossitis improved within one week and serum levels of vitamin C returned to the normal range. In industrial countries, scurvy became a rare disease in healthy children. However, since a few years, cases are reported in children and teenagers with unbalanced diet coming from economically favoured families. These extreme cases are one of the signs of a more general deterioration of dietary habits in paediatric populations in our societies. This emphasizes the importance of effective nutritional education programs aimed towards both parents and children.

Introduction

A 4-year-old boy showed up in our department of Allergology with chronic glossitis persisting after several ineffective anti-fungal treatments extending over 8 months. The main complaint was a tongue burning sensation. Physical examination revealed a patchy depapillated tongue (Fig. 1). Usual food skin tests, European standard series of patch-tests, as well as toothpaste patch tests were performed in search of allergic reactions, but remained negative. Mycological investigations of the mouth and stools were also negative. A detailed dietary history over one week revealed an unbalanced diet consisting mainly of sausage, eggs, biscuits, chocolate and milk without any fresh fruits or vegetables.

Biological investigations showed a mild anemia (hemoglobin 11 g/l) and low serum ascorbic acid 2.2 mg/L (reference range: 6-14 mg/L) and folate levels 5.1 nM/L (reference range: 6-36 nM/L). Plasma levels of vitamins B12, B2, B6 and zinc were in the normal range. This led to the diagnosis of glossitis caused by vitamin C deficiency and the patient was treated with 250 mg per day of oral ascorbic acid for 15 days. His parents were educated about dietary modification to include fresh fruits and vegetables. The glossitis improved within one week and serum levels of vitamin C returned to the normal range.

In developing countries and in war zones, scurvy still remains a frequent disease of the paediatric population (1-3). In industrial countries, scurvy has become a rare disease affecting only children with psychiatric diseases such as

autism or mental retardation (4-6). Cases in infants have become rare since infant formulas are now enriched in vitamin C.

However, since 2000, ten cases have been reported in otherwise healthy children because of unbalanced diet. These cases concerned children older than 5 years of age (7-13), and two additional cases concerned infants (14-15). The clinical manifestations of scurvy are stereotyped and represented by a painful limp due to bone collagen loss and sometimes associated with gingivitis. Our patient presented glossitis, a rare form of scurvy not described since the 1970s (16).

Ascorbic acid is essential for the hydroxylation of proline in pre-collagen. Humans lack the enzyme needed to synthesize ascorbic acid from glucose and thus require ascorbic acid in their diet. In vitamin C deficiency, pre-collagen cannot adopt the triple helix configuration indispensable for the fibrillar structure of collagen. As a consequence, all tissues and organs containing collagen can be affected. This explains the diversity of symptoms in scurvy. Ascorbic acid is mainly contained in fresh fruits and vegetables. The recommended daily allowance of vitamin C for infants and children are 35 and 45 to 50 mg

per day, respectively. This vitamin is destroyed by heat and oxidation. Indeed, ordinary cooking decreases food's vitamin C content by 20 to 40% (17). Even in orange juice, this content is variable and decreases over time with storage (18).

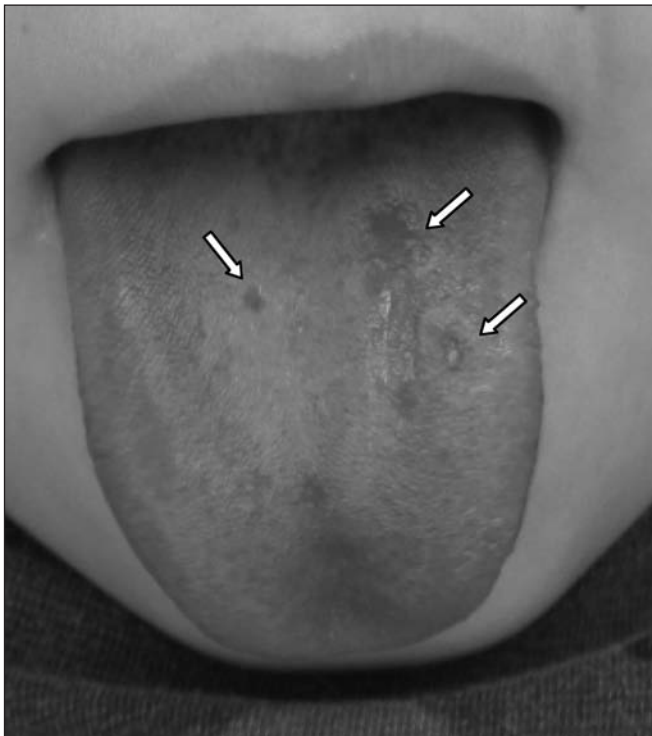
Thus, scurvy still occurs in developed countries in healthy children and remains difficult to diagnose because of the diversity of its clinical manifestations.

In spite of advances in food and nutrition in industrial countries, scurvy can still occur, especially in healthy children and teenagers coming from economically favoured families. Many children have an industrial and little diversified diet, in agreement with their eating preference, without any kind of fresh fruit and vegetable. These extreme cases are probably one of the signs of a more general deterioration of dietary habits in paediatric populations, particularly those affected by the increased incidence of obesity. This emphasizes the importance of effective nutritional education programs aimed towards both parents and children.

References

1. Ratanachu-Ek S, Sukswai P, Jeerathanyasakun Y, Wongtapradit L. Scurvy in pediatric patients: a review of 28 cases. *J Med Assoc Thai* 2003; 86 (Suppl 3): S734-40.
2. Cheung E, Mutahar R, Assefa F, et al. An epidemic of scurvy in Afghanistan: assessment and response. *Food Nutr Bull* 2003; 24(3): 247-55.
3. Ratageri VH, Shepur TA, Patil MM, Hakeem MA. Scurvy in infantile tremor syndrome. *Indian J Pediatr* 2005; 72(10):883-4.
4. Shetty AK, Steele RW, Silas V, Dehne R. A boy with a limp. *Lancet* 1998; 351(9097): 182.
5. Monks G, Juracek L, Weigand D, Magro C, Cornelison R, Crowson AN. A case of scurvy in an autistic boy. *J Drugs Dermatol* 2002; 1(1): 67-9.
6. Weinstein M, Babyn P, Zlotkin S. An orange a Day Keeps the Doctor Away: Scurvy in the year 2000. *Pediatrics* 2001;108(3):e55.
7. Tamura Y, Welch DC, Zic JA, Cooper WO, Stein SM, Hummel DS. Scurvy presenting as a painful gait with bruising in a young boy. *Arch Pediatr Adol Med* 2000;154(7):732-5.
8. Akikusa JD, Garrick D, Nash MC. Scurvy: forgotten but not gone. *J Paediatr Child Health*. 2003;39(1):75-7.
9. Bingham AC, Kimura Y, Imundo L. A 16-year old boy with purpura and leg pain. *J Pediatr*. 2003;142(5):560-3.
10. Rosati P, Boldrini R, Devito R, et al. A child with painful legs. *Lancet*. 2005 16-22;365(9468):1438.
11. Burns K, Camitta B. Pyrite or true gold. *J Pediatr Hematol Oncol* 2005; 27(12): 696-8.
12. Vitale A, La Torre F, Martini G, et al. Arthritis and gum bleed-

Figure 1



- ding in two children. *J Paediatr Child Health* 2009; 45(3): 158-60.
13. Bacci C, Sivoletta S, Pellegrini J, Favero L, Berengo M. A rare case of scurvy in an otherwise healthy child: diagnosis through oral signs. *Pediatr Dent* 2010; 32(7): 536-8.
 14. Narchi H, Thomas M. A painful limb. *J Paediatr Child H* 2000; 36(3): 277-8.
 15. Popovich D, McAlhany A, Adewumi AO, McKim Barnes M. Scurvy: Forgotten but definitely not gone. *J Pediatr Health Care* 2009; 23(6): 405-15.
 16. Taylor G. Letter: vitamins and the elderly. *Lancet* 1974 18;1 (7864): 1003.
 17. Hirschmann JV, Raugi GJ. Adult scurvy. *J Am Acad Dermatol* 1999; 41: 895-906.
 18. Johnston CS, Bowling DL. Stability of ascorbic acid in commercially available orange juices. *J Am Diet Assoc* 2002; 102(4): 525-9.