

M. GELARDI¹, G. PASSALACQUA², M.L. FIORELLA¹, N. QUARANTA¹

Assessment of biofilm by nasal cytology in different forms of rhinitis and its functional correlations

¹Department of Otolaryngology, University of Bari, Italy

²Allergy and Respiratory Diseases, University of Genoa Italy - E-mail: passalacqua@unige.it

KEY WORDS

Nasal cytology, biofilm, nasal obstruction, rhinitis, rhinomanometry

Corresponding author

Giovanni Passalacqua, MD
Allergy and Respiratory Diseases
Pad. Maragliano, L.go R.Benzi 10
13132 Genoa, Italy
Tel. +390103538933
Fax +390103538904
E-mail passalacqua@unige.it

SUMMARY

Background: Recently, it has been reported that nasal cytology in light microscopy can identify biofilms, which appear as cyan-stained "Infectious Spots". We assessed by the same method and in the same population, the presence of biofilms in different nasal disorders, and estimated if a correlation with the functional grade of obstruction existed. **Methods:** Subjects suffering from different nasal disorders, after a detailed clinical history and ENT examination, underwent nasal fibroendoscopy, skin prick test, rhinomanometry and nasal cytology. The presence of biofilm was linked to the type of disease and to the grade of obstruction. **Results:** Among 1,410 subjects previously studied, the infectious spot was found in 107 patients (7.6%), and this percentage reached 55.4% in subjects with cytologic signs of infectious rhinitis (presence of bacteria/fungi). Biofilms were largely more frequent in patients with adenoid hypertrophy (57.4%), followed by nasal polyposis (24%), chronic rhinosinusitis (9.5%) and non-allergic rhinitis (7.6%). Nasal cytology was normal in the remaining patients, where no infectious spot was detectable. Statistical analysis showed that nasal resistances were significantly higher in presence of biofilms in patients with adenoid hypertrophy ($p=0.003$), nasal polyposis ($p<0.001$), chronic rhinosinusitis ($p=0.018$) and septal deviation ($p=0.001$). **Conclusion:** The results demonstrate that biofilm is present not only in infectious rhinitis, but also in inflammatory and/or immune-mediated diseases. The presence of biofilms significantly correlates with the degree of nasal obstruction as assessed by rhinomanometry.

Introduction

Biofilms are surface-associated agglomerates of microorganisms (either bacteria or fungi) embedded in a self-produced extracellular polymeric matrix (1). Biofilms have been described in numerous disorders, including ENT diseases (e.g. rhinosinusitis, otitis, nasal polyposis) (2-4). The main clinical importance of biofilm resides in the fact that the polysaccharide matrix may be responsible for increased survival of microorganisms and for antibiotic re-

sistance, thus leading to a more difficult eradication or to a difficult-to-treat contamination of implanted medical devices. Consequently, identification of biofilm in vivo, has both diagnostic and therapeutic implications.

Due to their nature, biofilms have been always studied by complex and expensive techniques (i.e. electron microscopy or confocal laser microscopy) (5, 6), so that the study of biofilms cannot be applied in the routine clinical practice and in large-prevalence conditions, such as nasal diseases are. In a recent work it was demonstrated that

nasal cytology, performed by optical microscopy, is able to identify biofilms on nasal mucosal surfaces (7). According to this approach, biofilms appear as cyan-stained “Infectious Spots”, where the periodic acid Schiff staining confirm the presence of a polysaccharide matrix. In the previous work we aimed at validating the methodological approach, whereas in the present one we report, in the same population, the distribution of biofilms in different nasal diseases, and attempt to assess if a functional relation exists between biofilms and nasal obstruction.

Patients and methods

As previously described (7), the investigated population involved 1,410 subjects, referred as first visit (no previous ENT diagnostic procedures or intervention) to the Rhinology Clinic of the Otolaryngology Department of the University of Bari for nasal diseases. 60 subjects referred for non-nasal diseases served as control group. All subjects underwent detailed clinical history, ENT examination, nasal fibroendoscopy, skin prick test, rhinomanometry and nasal cytology. All patients provided an informed consent, and the observational study was notified to the Ethical Committee.

Skin prick tests to assess allergic rhinitis were carried out according to guidelines, with a panel of commercial extracts including: house dust mites, cat, dog, grasses, ragweed, Parietaria, birch, hazel tree, olive tree, *Alternaria tenuis*, *Cladosporium*, and *Aspergillum* (8). Nasal endoscopy was performed with a 3.4 mm flexible endoscope (ENT Vision Sciences®-USA). Adenoid hypertrophy was classified according to the degree of choanal obstruction in 4 grades (9); from grade I (obstruction < 25%) to grade IV (> 75% obstruction). Nasal polyposis was classified according to Lund and Mackay (10): stage I patients presented nasal polyps confined to the middle or superior meatus, stage 2 had polyps outside the middle meatus, in the sphenoidal recess or in the olfactory fissure and stage 3 had a massive polyposis. Nasal airflow resistance was measured by active anterior electronic rhinomanometry. Patients wore a tight-fitting face mask, and breathed through one nostril keeping the mouth closed. A sensor, placed in the contralateral nostril, recorded pre- and post-nasal pressures via airflow and pressure transducers (Rhinomanometer Menfis, Amplifon Italy). Nasal resistance was measured in Pa/mL/sec, The mean value of 4 or more airflow measurements were performed in each patient, and the mean value was recorded. The patients were classified in

3 groups according to the total resistance values: Group 1: ≤ 0.25 Pa/mL/sec, group 2: 0.25-2.50 Pa/mL/sec and group 3 > 2.50 Pa/mL/sec. Nasal cytology was performed by anterior rhinoscopy, and consisted of scrapings from the middle portion of the inferior turbinate, using a Rhino-Probe. The scraped material was transferred on a glass slide, air-dried and stained by May-Grunwald Giemsa (MGG) (Carlo Erba, Milan, Italy). The “infectious spot”, expression of biofilms, appeared as typical cyan-color patches including bacteria or fungi (7, 11). The slides were examined by a Nikon E600 light microscope (Nikon, Canada) and 50 microscopic fields were read at a magnification of 1000 x, to assess the presence of normal and abnormal cellular elements. A semi-quantitative grading was used, according to Meltzer (12). We considered as abnormal those cytograms where neutrophils represented more than 50%, eosinophils more than 20% and mast cells more than 10% of total cells recovered. The presence of bacteria and/or fungal spore was graded as follows: Grade 0= not visible; Grade 1+=occasional groups; Grade 2+=moderate number; Grade 3+=easily visible; Grade 4+=covering the entire field. Statistical analysis was performed by parametric test using a statistical software (Sigma Stat); significance was set at $p < 0.05$.

Results

The above mentioned studied group involved 1,410 patients (58.5% male, mean age 32 years, age range 2-74 years)(7), whereas the control group was increased to 60 patients (28 male, mean age 42.6 years, age range 5-72 years) suffering from non-nasal disorders, all with negative clinical history for nasal diseases and negative skin prick tests. The overall results of the diagnostic procedures, as detailed above, are summarized in figure 1.

The infectious spot (expression of biofilm) was identified in 107 (7.6%) patients which accounted for 55.4% of those patients with cytologic signs of infectious rhinitis (presence of bacteria/fungi). The presence of biofilm widely varied according to disease (Tab. 1), Biofilms were present in 57.4% of patients with adenoid hypertrophy (Fig. 2a). In this case, there were biofilms in 10% of patients with grade II (1/10), 57% of patients with grade III (16/28) and in 100% (14/14) of patients with stage IV disease. Thus, biofilms were significantly more frequent in patients with grade III and IV adenoid hypertrophy as compared to grade I and II ($p < 0.001$). Biofilm was detected in 24% of patients with nasal polyposis (Fig. 2b).

Figure 1 - Pie chart showing the distribution of diseases among 1,410 subjects. Percentages are also indicated

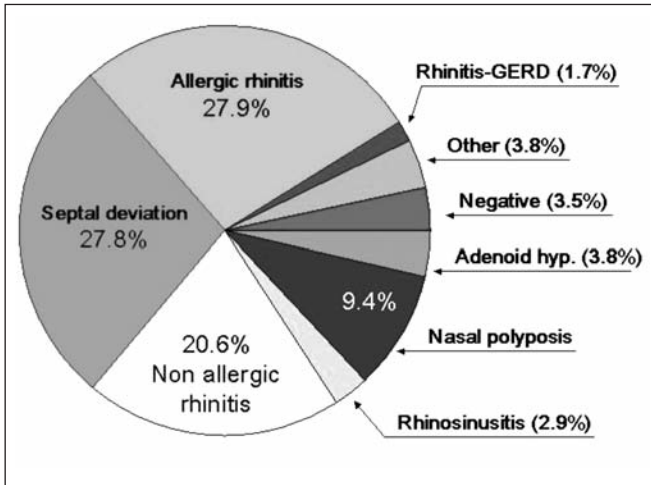


Table 1 - Patients with positive biofilm at nasal cytology in different diseases

Diagnosis	Patients N	Biofilm positive N (%)
Adenoid hypertrophy	54	31 (57.4)
Nasal polyposis	133	32 (24)
Rhinosinusitis	42	4 (9.5)
Non allergic rhinitis	290	22 (7.6)
Allergic Rhinitis	394	12 (3)
Septal deviation	392	6 (1.5)
Rhinitis + GERD	25	0
Other (rh.medicamentosa, septal perforation, post viral anosmia, antro-choanal polyposis)	30	0
ENT negative	50	0
Total	1410 (100)	107 (100)

Also in this case, their presence was significantly more frequent in grade 3 polyposis as compared to grade 1 and 2 ($p < 0.001$). Biofilms were also identified in 22 (7,6%) patients with non-allergic “cellular” rhinitis, (Fig. 2c), and in 9.5% patients with chronic rhinosinusitis (Fig. 2d). Nasal cytology was normal in the remaining patients and in the control group.

The results of rhinomanometry, that expresses the degree of nasal obstruction, are reported in table 2, according to

the presence or the absence of detectable biofilm. The statistical analyses showed that nasal resistances were significantly higher in the presence of biofilms in patients suffering by high-grade adenoid hypertrophy ($p = 0.003$), nasal polyposis ($p < 0.001$), chronic rhinosinusitis ($p = 0.018$) and septal deviation ($p = 0.001$). In patients with allergic and non-allergic rhinitis no significant difference was found between the two groups ($p = 0.298$ and $p = 0,054$).

Discussion

Biofilms are of relevant importance in many diseases, especially when mucosal surfaces are involved, thus also in ENT diseases (chronic rhinosinusitis, nasal polyposis, adenoid hypertrophy or otitis media), where mucosae themselves are the principal target organ. Our biological knowledge on biofilms is quite advanced, but there are few large-scale clinical applications of that knowledge, since biofilms can be studied only by complex techniques, not suitable for the usual clinical practice. Indeed, some Authors have shown that biofilms can be identified also at light microscopy (7, 13), especially using the simple May Grunwald-Giemsa staining. After validating the technical aspects of the identification of biofilm by nasal cytology, we attempted to assess the prevalence of biofilms in different nasal disorders, and to establish a correlation, if any, with nasal patency, that can be reliably measured with rhinomanometry. Our results demonstrate that biofilms are overall infrequent in nasal diseases, as they were identified only in 7.6% patients. On the other hand, more than 50% patients with cytological signs of infection (presence of bacteria/fungi) carried biofilms. On their mucosae. Biofilm was detected more frequently in adenoid hypertrophy (57.4%), followed by nasal polyposis (24%), chronic rhinosinusitis (9.5%), and non-allergic rhinitis (7.6%), whereas only few patients with allergic rhinitis (3%) and septal deviation (1.5%) displayed biofilm. The statistical analyses confirmed that the presence of biofilms was significantly more frequent in those patients with a higher degree of nasal obstruction.

Nasal infections are considered as a consequence of nasal obstruction (“a cavity that does not ventilate become infected”). Colonization of nasal mucosa by bacteria organized in biofilms may be, however, either the effect or the cause of chronic nasal obstruction. In the former case an obstructed nasal cavity favors the retaining of secretions and bacterial colonization, whereas, in the latter case, colonization by biofilms may inhibit the effect of medical

Figure 1 - a) Adenoid Hypertrophy; b) Nasal polyposis; c) NARES; d) Chronic rhinosinusitis. Infectious spot (biofilm) appears in cyan colour (IS). Within the spots bacteria (B), fungi (F) and eosinophils (E) are evidenced. Staining MGG – Magnification 1000X.

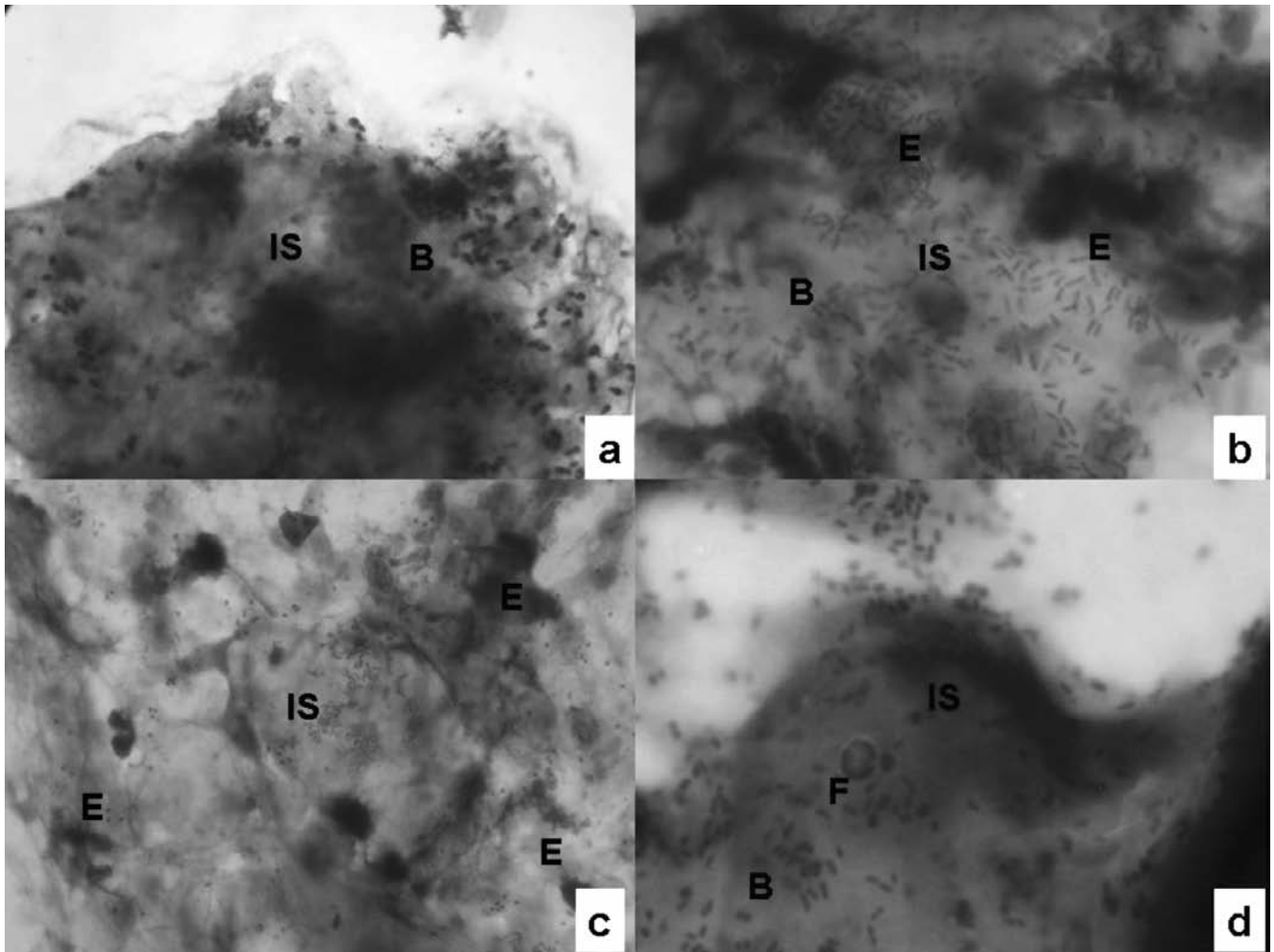


Table 2 - Total nasal resistance (active anterior rhinomanometry) according to the presence of biofilms

	N	Biofilm negative N (%)			Biofilm positive N (%)			P value
		≤0.25 Pa/mL/s	0.26-2.50 Pa/mL/s	>2.50 Pa/mL/s	≤0.25 Pa/mL/s	0.26-2.50 Pa/mL/s	>2.50 Pa/mL/s	
Adenoid hyperthropy	54	-	15 (65.2)	8 (34.8)	-	1 (3.2)	30 (96.8)	0.03
Nasal polyposis	133	-	91 (90)	10 (9.9)	-	3 (9.3)	29 (90.7)	<0.001
Rhinosinusitis	42	3 (7.9)	30 (79)	5 (13.1)	-	1 (25)	3 (75)	0.018
Non allergic rhinitis	290	6 (2.2)	104 (38.8)	158 (58.9)	-	6 (27.2)	16 (72.8)	NS
Allergic rhinitis	394	12 (3.1)	176 (46)	194 (50.8)	-	2 (16.7)	10 (83)	NS
Septal deviation	392	-	274 (70.2)	118 (29.8)	-	-	6 (100)	<0.01

therapies and induce mucosal hypertrophy, thus reducing nasal patency.

The present study suggests that both mechanisms may occur, since a positive correlation between nasal resistance and biofilms was found in all diseases, independent of their infectious nature. Thus, severe adenoid hypertrophy and grade 3 nasal polyposis, associated with increased nasal resistances, may favor biofilm formation, and biofilms may contribute to adenoid hypertrophy or to dimensions of nasal polyps. Also patients with septal deviation had biofilms, but only when the nasal obstruction was severe, due to inferior turbinate hypertrophy.

Non-allergic rhinitis is a unique group of diseases characterized by chronic nasal obstruction, sustained by a mucosal inflammatory infiltrate. Rhinocytograms of these patients are characterized by eosinophils and mast-cells mostly degranulating. In those patients, bacteria organized in biofilms were present in 7.6% of cases and did not correlate with nasal obstruction as assessed by rhinomanometry. A possible reason for this, may be that in such patients the cellular infiltrate plays the major role in the dimension of inferior turbinates and therefore in nasal obstruction (14, 15). We also found an unexpected low prevalence of biofilms (3%) in chronic rhinosinusitis, but this may be attributed to the sampling method, since specimen were obtained from the middle portion of the inferior turbinate, and therefore the inferior meatus could be not involved because of the natural draining pathways. When specimen are obtained close to the affected sinuses, a high prevalence of biofilms has been reported (16).

In conclusion, this study shows that biofilm is present not only in infectious nasal diseases, but also in inflammatory and immune-mediated disorders. Certainly, the presence of biofilm is more frequent in patients with a high degree of nasal obstruction. The possibility of identifying biofilm with a cheap and simple technique, such as nasal cytology, opens the way to diagnostic and therapeutic applications in both allergy and ENT fields of interest.

References

1. Costerton JW, Lewandowski Z, Caldwell DE, et al. Microbial biofilms. *Annu Rev Microbiol* 1995; 49: 711-45.
2. Vlastarakos PV, Nikolopoulos TP, Maragoudakis P, et al. Biofilms in Ear, Nose, and Throat Infections: How Important are They? *Laryngoscope* 2007; 117: 668-73.
3. Ferguson BJ, Stolz DB. Demonstration of biofilm in human bacterial chronic rhinosinusitis. *Am J Rhinol* 2005; 19: 452-7.
4. Al-Mazrou KA, Al-Khattaf AS. Adherent biofilms in adenotonsillar diseases in children. *Arch Otolaryngol Head Neck Surg* 2008; 134: 20-3.
5. Marrie TJ, Costerton JW. Scanning and transmission electron microscopy of in situ bacterial colonization of intravenous and intraarterial catheters. *J Clin Microbiol* 1984; 19: 687-93.
6. Hoa M, Tomovic S, Nistico L, et al. Identification of adenoid biofilms with middle ear pathogens in otitis-prone children utilizing SEM and FISH. *Ann Int J Pediatr Otorhinolaryngol* 2009; 73: 1242-8.
7. Gelardi M, Passalacqua G, Fiorella MI, Mosca A, Quaranta N. Nasal cytology: the "infectious spot", an expression of a morphological-chromatic biofilm. *EJCMID* 2011 (in Press).
8. Dreborg S. EAACI Subcommittee on Skin Tests. Skin tests used in type I allergy testing. Position Paper. *Allergy* 1989; 44: 1-51.
9. Cassano P, Gelardi M, Cassano M, et al. Adenoid tissue rhinopharyngeal obstruction grading based on fiberoendoscopic findings: a novel approach to therapeutic management. *Int J Pediatr Otorhinolaryngol* 2003; 67: 1303-9.
10. Lund VJ. Surgical outcomes in chronic rhinosinusitis and nasal polyposis. *Rhinology* 2006; 44: 97.
11. Gelardi M. Atlas of nasal cytology. Turin, Italy: Centro Scientifico Editore; 2006.
12. Meltzer EO, Jalowayski AA. Nasal cytology in clinical practice. *Am J Rhinol* 1988; 2: 47-54.
13. Hochstim CJ, Choi JY, Lowe D, Masood R, Rice DH. Biofilm detection with hematoxylin-eosin staining. *Arch Otolaryngol Head Neck Surg* 2010; 136: 453-6.
14. Cohen M, Kofonow J, Nayak JV, et al. Biofilms in chronic rhinosinusitis: a review. *Am J Rhinol Allergy* 2009; 23: 255-60.
15. Foreman A, Psaltis AJ, Tan LW, Wormald PJ. Characterization of bacterial and fungal biofilms in chronic rhinosinusitis. *Am J Rhinol Allergy* 2009; 23: 556-61.
16. Healy DY, Leid JG, Sanderson AR, Hunsaker DH. Biofilms with fungi in chronic rhinosinusitis. *Otolaryngol Head Neck Surg* 2008; 138: 641-7.