Eur Ann Allergy Clin Immunol Vol 49, N 3, 138-142, 2017

P. Gamba[1], C. Lombardi[2]

Eosinophil fungal rhinosinusitis caused by Fusarium infection secondary to odontogenic maxillary sinus disease: when collaboration between otolaryngologist and allergologist leads to the correct diagnosis and therapy

[1]Department of Otolaryngology, Head and Neck Surgery, Poliambulanza Foundation Hospital, Brescia, Italy
[2]Departmental Unit of Allergology, Clinical Immunology and Pneumology, Poliambulanza Foundation Hospital, Brescia, Italy

Key words

Odontogenic sinusitis; Eosinophil Fungal Rhinosinusitis; Functional Endoscopic Sinus Surgery; dental implants; Schneiderian membrane

Corresponding author
Carlo Lombardi
Departmental Unit of Allergology, Clinical Immunology and Pneumology
Poliambulanza Foundation Hospital
Via Leonida Bissolati 57, 25124 Brescia, Italy
Phone: +39 030 35 18 555
E-mail: carlo.lombardi@poliambulanza.it

Summary

Rhinitis and sinusitis usually coexist and are concurrent in most individuals; thus, the correct terminology is now "rhinosinusitis". On the basis of numerous causative factors, often co-existing in the same patient, the diagnosis of rhinosinusitis is also made by a wide variety of practitioners (allergologists, otolaryngologists, pulmonologists, primary care physicians, paediatricians, and many others). Approximately 5-15% of the population suffers from chronic rhinosinusitis, and in 10-12% of them, it is of dental origin. The treatment of odontogenic maxillary sinus disease is directed to the management of the rhinosinusitis and of the odontogenic source. The widespread use of dental implants and reconstructive procedures for dental implant placement has led to new types of complication, as in this case report, due to chronic eosinophilic rhinosinusitis secondary to Fusarium infection in the maxillary sinus. The patient was initially evaluated by the allergologist, and subsequently successfully treated by the otolaryngologist with Functional Endoscopic Sinus Surgery. The advantages of endoscopic sinus surgery include more accurate visualization, no external incision, reduced soft tissue dissection, and reduced hospital stay. Chronic maxillary sinusitis of dental origin is a common disease that requires treatment of the sinusitis as well as of the odontogenic source.

Introduction

Chronic rhinosinusitis with (CRSwNP) and without nasal polyps (CRSsNP) in its many forms, constitutes one of the commonest conditions encountered in medicine and may present to a wide range of clinicians from primary care to accident and emergency, pulmonologists, allergists, otorhinolaryngologists and even intensivists and neurosurgeons when severe complications occur (1,2). Odontogenic rhinosinusitis is a relevant infectious condition of the paranasal sinuses. Approximately 5-15% of the population suffers from chronic rhinosinusitis, and in 10-12% of them, it is of dental origin (3). The widespread use of dental implants and reconstructive procedures for dental implant placement has led to new types of complication as a chronic eosinophilic rhinosinusitis secondary to infective agents in the maxillary sinus (4). Frequently, patients have a delayed diagnosis and are initially evaluated by various specialists, such as allergists (5). We present a case report of eosinophil fungal rhinosinusitis caused by Fusarium infection secondary to odontogenic maxillary sinus disease, successfully treated by the otolaryngologist with Functional Endoscopic Sinus Surgery (FESS). The advantages of endoscopic sinus surgery include

more accurate visualization, no external incision, reduced soft tissue dissection, and reduced hospital stay. Chronic maxillary sinusitis of dental origin is a common disease that requires treatment of the sinusitis as well as of the odontogenic source. Dental Implantation can occasionally be compromised by anatomical limitations, as well as by the status of alveolar bone and surrounding soft tissue. Implantation around the posterior maxilla area is often challenging because of alveolar bone resorption, sinus pneumatization or other reasons. Therefore, implants should be treated constantly after surgery. Improving the success rate of implant placement in the molar area requires an accurate functional and anatomical understanding of the maxillary molar area, as well as of potential complications that may arise during and after surgery and their appropriate management (6).

Case Report

A 55-year-old, Caucasian, male patient was sent for evaluation to our ENT department after a previous allergologic evaluation, that had excluded an allergic cause of the chronic rhinosinusal symptoms. The patient reported a considerable pain in the left zygomatic area with headache in the left temporal region. The patient had a history of dental extraction of the number 26, and underwent single dental implant installation. Medical therapy was administered, including empirical antibiotics (penicillin, clindamycin), non-steroidal anti-inflammatory drugs, expectorants and antihistamines, which were prescribed to mitigate symptoms; however, the patient showed no improvement after 4 weeks of follow-up, and the persistence of signs and symptoms of discomfort indicated that further investigation was needed. Panoramic view revealed that the single implant was protruding into the left maxillary sinus, and that the radiopacity of the sinus was increased (**figure 1**). Coronal view computed tomography (CT) revealed definite signs of sinusitis, with opacification of the left maxillary sinus as well as ethmoidal sinus, and confirmed that

Figure 1 *- Panoramic view, left maxilla sinus bone grafting and #26 implantation revealed dental implant protrusion into the left maxillary sinus.*

Figure 2 *- Paranasal sinuses computed tomography revealed mucosal thickening and opacification with air bubbles in the left maxillary sinus and the presence of "high and low density areas" material into the sinus with a central gutta-percha pin. Coronal CT images revealed radiopaque concretion in the left maxillary sinus in a typical mycosis, in this case Eosinophil Fungal Rhinosinusitis type Fusarium.*

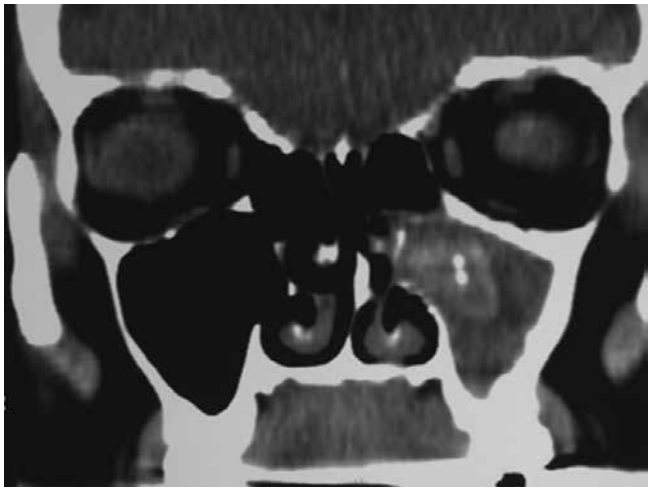

Figure 3 *- MRI, axial T2-weighted image demonstrates a fluid level with high signal level with high signal posteriorly.*

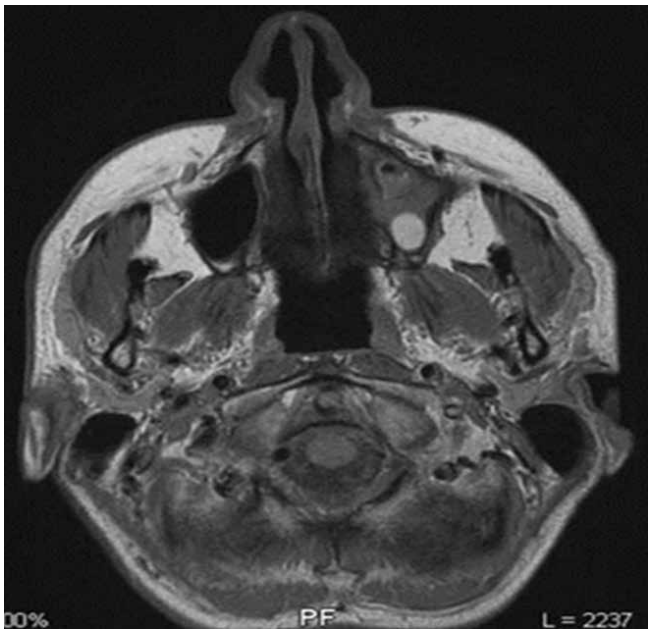

a dental implant was protruding approximately 5 mm into the sinus (**figure 2**). MRI, axial T2-weighted image demonstrated a fluid level with high signal level with high signal posteriorly (**figure 3**). Based on this evidence of obstruction of the ostium of the left nasal cavity and infection of the mucocele of the left maxillary sinus, we consulted Oral-Maxillofacial surgeon and concluded that an intranasal approach alone would be sufficient to remove the mucocele, and FESS was performed. The middle turbinate was widely excised so that pus and infected bone graft particle could be flushed from the sinus cavity. The ostium was exposed by removal of the uncinated process on the middle meatus to access to ostium and the ethmoidal sinus. Edematous, hyperplastic nasal mucosa within the sinus was enucleated after the natural ostium was surgically enlarged (**figure 4**) then the sinus was irrigated with normal saline until no additional free-floating particles were observed. During this procedure, the dental implant was not removed because of nasal discharge stopping and increased radiopacity. The implant was left stable. The patient received absorbent nasal packing for 2 days, no complications occurred and symptoms improved gradually over the healing period. The patient was followed up for 5 weeks at the ENT Department, with progressive improvement (**figure 5**). Histological examination revealed typical fungal masses, an eosinophil fungal rhinosinusitis type Fusarium, on injured mucosa and on crystallization cores with a central gutta-percha pin (Grocott) (**figure 6**). The patient's immunological profile study did not document a condition of immunodeficiency (which occurs in many patients with infection by Fusarium).

Figure 4 *- Endoscopic view, left maxillary sinus, the fungal concretion is recognizable. Further purulent secretion with fungal spores is evacuated through the natural ostium.*

Figure 5 *- Endoscopic view: condition 2 months after functional endoscopic sinus surgery (FESS), after uncinectomy and maxillary sinus ostium enlargement. After aspiration of thickened pus the base of the left maxillary sinus was found, reaching freely into the lumen.*

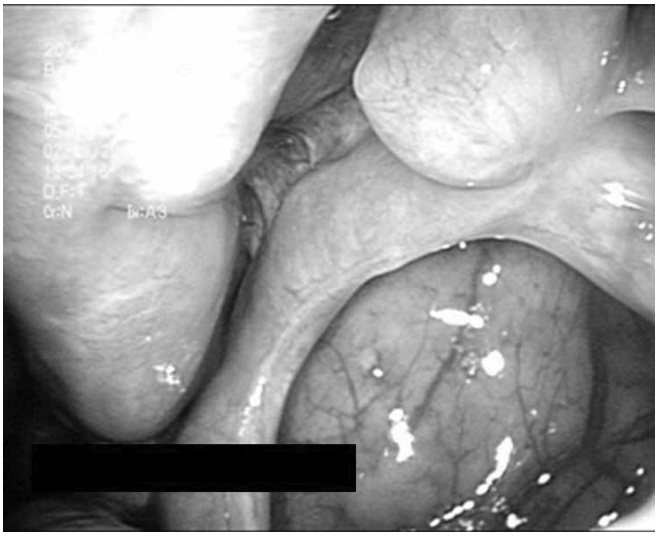

Figure 6 *- Histological examination revealed typical fungal masses, an eosinophil fungal rhinosinusitis type Fusarium, on injured mucosa and on crystallization cores with a central gutta-percha pin (Grocott).*

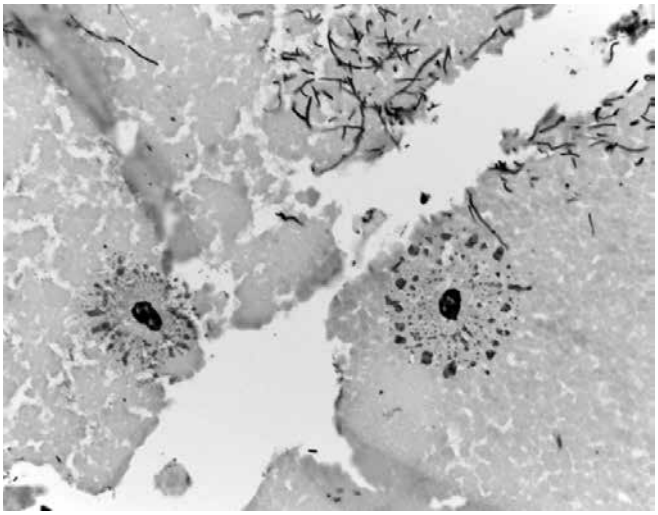

Discussion

In many cases of maxillary sinusitis, dysfunction of mucociliary clearance is a major clinical problem. The stagnation of secretions and obstruction of excretion from and ventilation

within the maxillary sinus are predisposing factors for sinus infection. The area between middle turbinate and lateral nasal wall often has an anatomical variation; therefore, edema of the mucosa can result in obstruction of the ostium and dysfunction of mucociliary. Maxillary sinus floor lift has been reported to cause postoperative sinusitis. The elevation of the Schneiderian membrane could affect a sinus homeostasis and lead to sinusitis by temporal obstruction of a physiological sinus drainage through the osteomeatal unit. Mucosal inflammation caused by misplaced implant can similarly cause mucosal inflammation and stenosis of the osteomeatal unit with detrimental effect on sinus ventilation. Recommended treatment for dental implant-related sinusitis typically involves surgical restoration for proper drainage and ventilation of the sinus, interrupting the described sequence of events that lead to sinus infection. FESS is a relatively recent surgical procedure used in the treatment of maxillary sinusitis (7,8). Simple elimination of the irritating stimulus, such as exposed or displaced implant, could also be considered. Reported in the literature indicated that implant exposure greater than 4 mm from the sinus floor can give rise to sinusitis or rhinosinusitis. In this report the implant fixture was not removed due to not only the exposed length (4 mm), but also the significant stability. In the posterior molar region, where implant placement is difficult, many complication of maxillary sinus sequent implant placement can occur. The symptoms of acute maxillary sinusitis include discomfort or pain in the facial area and nasal discharge (9). Chronic maxillary sinusitis arises from obstruction of the ostium of the paranasal sinus. There is destruction of the epithelium, with progressive infection that leads to irreversible changes. The maxillary ostium is located close to the maxillary roof, and the maxillary sinus floor is located about 0.5 cm below the nasal floor. The consequent welling of the maxillary mucosa makes paranasal ostium drainage difficult. Occlusion of the osteomeatal unit can reduce the drainage of discharge and the ventilation of the paranasal cavity whereby inducing paranasal sinusitis. When the inside of the maxilla is overfilled with bone graft materials, it can induce necrosis of the maxillary cavity (10). In addition, the loss of bone materials within the maxillary cavity can lead to maxillary sinusitis. Perforation of the maxillary sinus membrane during dental implant placement can also induce maxillary sinusitis. Perforation of the maxillary sinus membrane can allow the graft material, particularly synthetic bone powder, to escape from the maxillary sinus through the nose, and also it impedes the mucociliary action of the maxillary sinus membrane and leads to infection (11,12). The most common form of mycoses is the non-invasive, saprophytic maxillary sinus mycoses (13). In the present case, histological examination revealed an eosinophil fungal rhinosinusitis type Fusarium, on injured mucosa and on crystallization cores that fill a maxillary sinus, but are only invasive in the rarest cases. They require thorough surgical removal, whereby attention must be paid to good ventilation of the affected paranasal sinus (14). In this case of the maxillary sinus, the mass can be removed thorough functional endoscopic sinus surgery, after suitable widening of the natural ostium. It is important to get a good overview of the maxillary sinus, e.g. with a 70° telescope. Relapses after mycoses almost always represent reinfection caused by fungal material left behind (15). Fusarium species cause a broad spectrum of infections in humans, including superficial infections such as keratitis and onychomycosis, as well as locally invasive and disseminated infections (16). Invasive and disseminated infections occur almost exclusively in severely immunocompromised patients, particularly among those with prolonged and profound neutropenia and/or severe T cell immunodeficiency. Among patients with hematologic malignancy, the infection predominates during periods of neutropenia, typically among patients with leukemia receiving induction chemotherapy. Fusarium species may also cause allergic diseases, such as sinusitis in immunocompetent individuals (17), and mycotoxicosis following ingestion of food contaminated by toxin-producing Fusarium species (18). Odontogenic sinusitis is a well-recognized, but understudied form of sinusitis. Odontogenic sinusitis requires unique diagnostic criteria and a treatment regimen that differs from non-odontogenic sinusitis. Odontogenic sinusitis is often misdiagnosed (19). Radiology reports commonly do not mention dental pathology (20). Management of odontogenic sinusitis needs to be tailored to each patient and many complex interplay specialist competencies involving medical management, dental surgery, and functional endoscopic sinus surgery (21).

References

1. Fokkens WJ, Lund VJ, Mullol J, Bachert C, Alobid I, Baroody F, Cohen N, Cervin A, Douglas R, Gevaert P, Georgalas C, Goossens H, Harvey R, Hellings P, Hopkins C, Jones N, Joos G, Kalogjera L, Kern B, Kowalski M, Price D, Riechelmann H, Schlosser R, Senior B, Thomas M, Toskala E, Voegels R, Wang de Y, Wormald PJ. European Position Paper on Rhinosinusitis and Nasal Polyps 2012. Rhinol Suppl. 2012;(23):3;1-298.
2. Leo G, Incorvaia C, Masieri S, Triulzi F. Imaging criteria for diagnosis of chronic rhinosinusitis in children. Eur Ann Allergy Clin Immunol. 2010;42:199-204.
3. Crovetto-Martínez, Martin-Arregui FJ, Zabala-López-de-Maturana A, Tudela-Cabello K, Crovetto-de la Torre MA. Frequency of the odontogenic maxillary sinusitis extended to the anterior ethmoid sinus and response to surgical treatment. Med Oral Patol Oral Cir Bucal. 2014;Mar8.
4. Hoskison E, Daniel M, Rowson JE, Jones NS. Evidence of an increase in the incidence of odontogenic sinusitis over the last decade in the UK. Laryngol Otol. 2012;126(1):43-6.
5. Longhini AB, Branstetter BF, Ferguson BJ. Otolaryngologists' perceptions of odontogenic maxillary sinusitis. Laringoscope 2012:122(9):1910-4.

6. Bourlidou E, Liokatis PG, Zouloumis L. Endoscopic assistance in the diagnosis and treatment of odontogenic maxillary sinus disease. Oral Maxillofac Surg. 2013Mar19.
7. Matsumoto Y, Okuno T, Hasegawa Y, Kuwauchi M. Dual antrostomy optical window for visualising sinus cavity during implant restoration. BMJ Case Rep. 2012Jun25;2012.
8. Felisati G, Chiapasco M, Lozza P, Saibene AM, Pipolo C, Zaniboni M, Biglioli F, Borloni R. Sinusal complications resulting from dental treatment outcome-oriented proposal of classification and surgical protocol. Am J Rhinol Allergy. 2013;27(4):e101-6.
9. Longhini AB, Ferguson BJ. Clinical aspects of odontogenic maxillary sinusitis: a case series. Int Forum Allergy Rhinol. 2011;1(5):409-15.
10. Najm SA, Malis D, Hage ME, Rahban S, Carrel JP, Bernard JP. Potential adverse events of endosseous dental implants penetrating the maxillary sinus: Long-term clinical evaluation. Laryngoscope. 2013;123(12):2958-61.
11. Cymerman JJ, Cymerman DH, O'Dwyer RS. Evaluation of odontogenic maxillary sinusitis using cone-beam computed tomography: three case reports. J Endod. 2011;37(10):1465-9.
12. Baĭdik OD, Logvinov SV, Zubarev SG, Sysoliatin PG, Gurin AA. Cone-beam computed tomography evaluation of maxillary sinusitis. Maillet M, Bowles WR, McClanahan SL, John MT, Ahmad M. J Endod. 2011;37(6):753-7.
13. Puglisi S, Privitera S, Maiolino L, Serra A, Garotta M, Blandino G, Speciale A. Bacteriological findings and antimicrobial resistance in odontogenic and non-odontogenic chronic maxillary sinusitis. J Med Microbiol. 2011;60(Pt 9):1353-9.
14. Giovannetti F, Priore P, Raponi I, Valentini V. Endoscopic sinus surgery in sinus-oral pathology. J Craniofac Surg. 2014;25(3):991-4.
15. Fanucci E, Nezzo M, Neroni L, Montesani L Jr, Ottria L, Gargari M. Diagnosis and treatment of paranasal sinus fungus ball of odontogenic origin: case report. Oral Implantol (Rome). 2014;6(3):63-6.
16. Nucci M, Anaissie E. Fusarium infections in immunocompromised patients. Clin Microbiol Rev. 2007;20:695.
17. Wickern GM. Fusarium allergic fungal sinusitis. J Allergy Clin Immunol. 1993;92:624.
18. Nelson PE, Dignani MC, Anaissie EJ. Taxonomy, biology, and clinical aspects of Fusarium species. Clin Microbiol Rev. 1994;7:479.
19. Patel NA, Ferguson BJ. Odontogenic sinusitis: An ancient but under-appreciated cause of maxillary sinusitis. Curr Opin Otolaryngol Head Neck Surg. 2014;20(1):24-8.
20. Shanbhag S, Karnik P, Shirke P, Shanbhag V. Association between periapical lesions and maxillary sinus mucosal thickening: a retrospective cone-beam computed tomographic study. J Endod. 2013;39(7):853-7.
21. Chiapasco M, Felisati G, Zaniboni M, Pipolo C, Borloni R, Lozza P. The treatment of sinusitis following maxillary sinus grafting with the association of functional endoscopic sinus surgery (FESS) and an intra-oral approach. Clin Oral Implants Res. 2013;24:623-9.