

VALERIA FABBRI<sup>1,2</sup> , VALERIA GIUSEPPINA RITA ORTOLANI<sup>1</sup> , LEA CARON<sup>1</sup> ,  
ELEONORA BONO<sup>1,2</sup> , CHRISTIAN PAOLO RATTI<sup>1,2</sup> , ENRICO IEMOLI<sup>1</sup> 

# Skin atrophy after skin tests with corticosteroids for the diagnosis of SARS-CoV-2 vaccine excipients hypersensitivity

<sup>1</sup>Allergy and Clinical Immunology Unit, ASST FBF Sacco, Milan, Italy

<sup>2</sup>Allergy and Clinical Immunology Residency, University of Milan, Milan, Italy

## KEY WORDS

*Hypersensitivity; vaccine anti SARS-CoV-2; atrophy; excipients; corticosteroids.*

## Corresponding author

Valeria Fabbri  
Allergy and Clinical Immunology Unit  
ASST FBF Sacco  
via Giovanni Battista Grassi 74  
20157 Milan, Italy  
ORCID: 0000-0001-9779-6110  
E-mail: valeria.fabbri@unimi.it

## Doi

10.23822/EurAnnACI.1764-1489.282

To the Editor,

in December 2020 the SARS-CoV-2 vaccination campaign got started and several adverse reactions rapidly were reported, including suspected mild and anaphylactic allergic reactions. Non-anaphylactic allergic type reactions showed an incidence of 11.6-43.8% cases per million first doses administered; however, anaphylactic reactions showed an incidence of 2.5-11.1% cases per million first doses administered (1, 2).

Right in the early stages of the worldwide SARS-CoV-2 vaccination campaign, vaccine excipients were hypothesized to be the culprits of the hypersensitivity reactions reported (3-6).

The SARS-CoV-2 excipients of the vaccines available in Italy, indicated as potential allergens, are:

- Comirnaty (Pfizer-BioNTech): Polyethylen glycol 2000 (PEG 2000);
- Spikevax (Moderna): Polyethylen glycol 2000 (PEG 2000), Trometamol;

- Vaxzevria (AstraZeneca): Polysorbate 80;
- Johnson & Johnson (Janssen): Polysorbate 80;
- Nuvaxovid (Novavax): Polysorbate 80.

Polyethylene glycols (PEGs) or macrogols are a family of hydrophilic polymers with a variable molecular weight ranging from 200 to 35,000 kDa. They can be found in drugs, as an active ingredient and as an excipient, in cosmetic and food products. The exposure to these substances commonly occurs both in house (*e.g.*, food additives, personal hygiene products), both in a medical-surgical environment (*e.g.*, laxatives, wound dressings, PEGylated drugs and hydrogels). Polysorbates or PEG sorbitans are PEG derivatives that share structural similarities with PEGs, and both are common excipients.

Skin Prick Tests (SPT) and Intradermal Tests (IDT) are used in the allergy practice in order to assess sensitization to active principles and to excipients, included the ones contained in SARS-CoV-2 vaccines as indicated by the main guidelines (7, 8).

Hypersensitivity to excipients, defined as inert substances, has always been thought as a rare occurrence. From 1977 to 2016, 37 cases of immediate hypersensitivity reaction to PEG were reported, 21 with skin test positivity (SPT and/or IDT), 2 with positive contact test, 1 with negative test and 13 without diagnostic test (9).

Nonetheless, at the present time the frequency of hypersensitivity to PEG and Polysorbates is still debated (10, 11).

Many patients were sent to allergy evaluation to confirm or exclude SARS-CoV-2 vaccine excipient allergy, upon indication of vaccinating centers or attending physicians. In most cases a detailed history allows the exclusion of excipient sensitization (12). In some selected patients, allergy work-up, including skin tests, is mandatory. The ever-increasing evidence has made it possible to identify that the subjects deserving such a diagnostic approach show at least one of these features: anaphylaxis to injectable drug or vaccine containing PEG or derivatives; anaphylaxis to oral/topical products containing PEG; recurrent anaphylaxis of unknown cause; suspected or confirmed allergy to any mRNA vaccine; confirmed allergy to PEG or derivatives (8).

In an emergency climate, the recommendation to vaccinate the entire population has raised fear of adverse effects. For this reason, skin tests have become a useful tool to rule out a state of hypersensitivity even when the medical history seemed to rule it out.

In Italy the use of the whole SARS-CoV-2 vaccine in allergy work-up has not been taken into account for ethical reasons, and some authors do not recommend skin testing with the vaccine because of lack of information about sensitivity or specificity and unclear safety of skin testing (13).

Therefore, the joint guidelines of the two main allergologic Italian societies recommend the use of PEG 3350 and steroid-based injectable formulations containing PEG 3350 or polysorbate 80 for the execution of SPT and IDT (7). According to these guidelines the drugs and concentrations used for skin tests are detailed in **table I**.

Between January 2021 and December 2021, 145 skin tests were carried out at our center. In this work we want to report the appearance of cutaneous atrophy at the intradermal site, which occurred in 12 patients (8.16%): seven patients had atrophy with Triamcinolone acetonide, three with Methylprednisolone acetate, one patient with both Triamcinolone acetonide and Methylprednisolone acetate, one patient with all steroids (**figure 1**).

This effect was mainly detected at the IDT sites with depot-corticosteroids that may remain in the skin for prolonged periods of time, even over a year (14).

The reactions appeared about one week after the test and proved present and unchanged even after six months. In a previous paper other authors had described skin atrophy in patients subjected to intradermal tests with steroids, in particular with Beta-methasone dipropionate and Triamcinolone acetonide, while no atrophy was noted for other steroids (15). To our knowledge, there have been no reports in the literature after performing the skin tests for the diagnosis of allergy to the preservatives of the anti-COVID vaccines.

The occurrence of skin atrophy has led us to change the informed consent for the skin tests procedures, by adding the possibility of such an adverse event.

Topical glucocorticoids skin atrophy is a well-known adverse effect (16): their atrophying effect manifests both in the epidermis and in the dermis. In the epidermis layer the antiproliferative effect and the acceleration of maturation of keratinocytes lead to a thinning of the stratum corneum. Epidermis also displays a loss of barrier integrity by reducing the synthesis of lipid components like ceramides, cholesterol, and fatty acids. In the dermal layer the antimetabolic effect on fibroblasts causes a loss of tensile strength and elasticity: at the molecular level this can be explained by a reduction in synthesis and increased degradation of the extracellular matrix proteins like collagen, proteoglycans and elastin (17, 18). The intensity of these effects depends on numerous pharmacokinetic (*e.g.*, vehicle lipophilia, depot as route of administration) and pharmacodynamic variables (*e.g.*, steroid potency) (18). In our case the effects of dermal atrophy are amplified by intradermal injection of the drug, even if diluted.

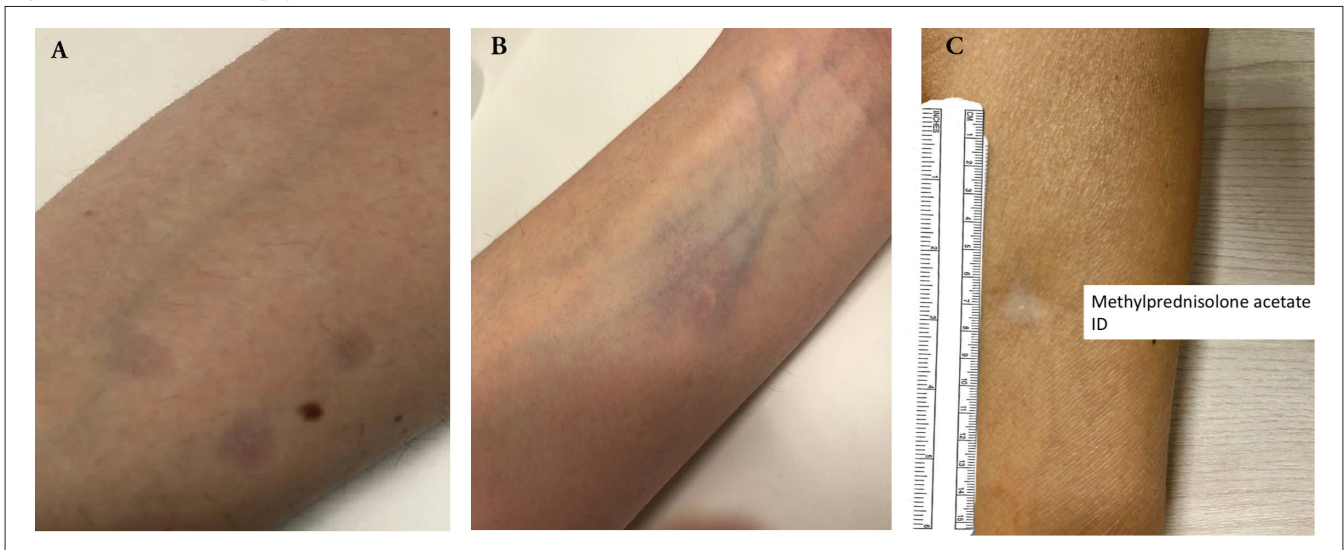
There is growing evidence that skin tests with PEG excipients and polysorbate play an increasingly limited role in identifying those at risk of developing hypersensitivity reactions to vaccines for COVID-19, with a positive and negative predictive value yet to be established (7, 19, 20).

Other hypothesis likewise emerge that immediate hypersensitivity reactions can be determined not only by PEG and polysorbates but also by the lipid nanoparticles that build up the envelope of vaccines to mRNA and the mRNA itself (21).

**Table I** - Non-irritating concentrations for skin tests with PEG 3350 and polysorbate 80 contained in steroids.

PEG 3350		Negative control	Polysorbate 80
Macrogol powder oral solution	Methylprednisolone acetate	Methylprednisolone sodium succinate	Triamcinolone acetonide
SPT 1:1	SPT 1:1 (40 mg/ml)	SPT 1:1 (40 mg/ml)	SPT 1:1 (40 mg/ml)
	IDT 1:10 (4 mg/ml)	IDT 1:10 (4 mg/ml)	IDT 1:1 (40 mg/ml)

Adapted from (7).

**Figure 1** - Cutaneous atrophy at the intradermal site.

(A) Skin atrophy with hyperpigmentation at the intradermal site of Methylprednisolone acetate 1:10 (upper lesion), Triamcinolone acetonide 1:1 and Methylprednisolone sodium succinate (left and right bottom lesions); (B) Skin atrophy surrounded by an hyperpigmented area at the intradermal site of Methylprednisolone acetate 1:10; (C) Skin atrophy with hypopigmentation at the intradermal site of Methylprednisolone acetate 1:10.

The low clinical-decision relevance of PEG and polysorbate steroid-based tests and the risk of potentially irreversible skin side effects would suggest that such diagnostics should be performed only in accurately selected patients and with positive skin test with whole vaccine (22, 23).

According to our experience, skin atrophy observed after skin tests procedures with steroids used to confirm or rule out sensitization to COVID-19 vaccine preservatives, is not such a rare occurrence and should be explained to the patient, before performing this procedure.

### Fundings

None.

### Contributions

VF: writing - original draft. VGO, LC: methodology. EB, CPR: investigation; El: conceptualization.

### Conflict of interests

The authors declare that they have no conflict of interests.

### References

1. CDC COVID-19 Response Team; Food and Drug Administration. Allergic Reactions Including Anaphylaxis After Receipt of the First Dose of Moderna COVID-19 Vaccine - United States, December 21, 2020-January 10, 2021. *MMWR Morb Mortal Wkly Rep.* 2021;70(4):125-9. doi: 10.15585/mmwr.mm7004e1.
2. CDC COVID-19 Response Team; Food and Drug Administration. Allergic Reactions Including Anaphylaxis After Receipt of the First Dose of Pfizer-BioNTech COVID-19 Vaccine - United States, December 14-23, 2020. *MMWR Morb Mortal Wkly Rep.* 2021;70(2):46-51. doi: 10.15585/mmwr.mm7002e1.
3. Cabanillas B, Akdis CA, Novak N. Allergic reactions to the first COVID-19 vaccine: A potential role of polyethylene glycol? *Allergy.* 2021;76(6):1617-8. doi: 10.1111/all.14711.
4. Caballero ML, Quirce S. Excipients as Potential Agents of Anaphylaxis in Vaccines: Analyzing the Formulations of Currently Authorized COVID-19 Vaccines. *J Investig Allergol Clin Immunol.* 2021;31(1):92-3. doi: 10.18176/jiaci.0667.
5. Borgsteede SD, Geersing TH, Tempels-Pavlica Z. Other excipients than PEG might cause serious hypersensitivity reactions in COVID-19 vaccines. *Allergy.* 2021;76(6):1941-2. doi: 10.1111/all.14774.
6. Klimek L, Novak N, Cabanillas B, Jutel M, Bousquet J, Akdis CA. Allergenic components of the mRNA-1273 vaccine for COVID-19: Possible involvement of polyethylene glycol and IgG-mediated complement activation. *Allergy.* 2021;76(11):3307-13. doi: 10.1111/all.14794.
7. Linee di indirizzo AAIITO e SIAAIC per la gestione da parte degli allergologi dei pazienti a rischio di reazioni allergiche per COVID-19. Disponibile at: <https://www.siaaic.org/?p=5569>. Last access date: 15/01/2021.
8. Barbaud A, Garvey LH, Arcolaci A, Brockow K, Mori F, Mayorga C, et al. Allergies and COVID-19 vaccines: An ENDA/EAACI Position paper. *Allergy.* 2022;77(8):2292-312. doi: 10.1111/all.15241.
9. Wenande E, Garvey LH. Immediate-type hypersensitivity to polyethylene glycols: a review. *Clin Exp Allergy.* 2016 Jul;46(7):907-22. doi: 10.1111/cea.12760.

10. Stone CA Jr, Liu Y, Relling MV, Krantz MS, Pratt AL, Abreo A, et al. Immediate Hypersensitivity to Polyethylene Glycols and Polysorbates: More Common Than We Have Recognized. *J Allergy Clin Immunol Pract.* 2019;7(5):1533-40.e8. doi: 10.1016/j.jaip.2018.12.003.
11. Bent RK, Faihs V, Tizek L, Biedermann T, Zink A, Brockow K. PEG allergy - A COVID-19 pandemic-made problem? A German perspective. *World Allergy Organ J.* 2022;15(11):100714. doi: 10.1016/j.waojou.2022.100714.
12. Brockow K, Mathes S, Fischer J, Volc S, Darsow U, Eberlein B, et al. Experience with polyethylene glycol allergy-guided risk management for COVID-19 vaccine anaphylaxis. *Allergy.* 2022;77(7):2200-10. doi: 10.1111/all.15183.
13. Banerji A, Wickner PG, Saff R, Stone CA Jr, Robinson LB, Long AA, et al. mRNA Vaccines to Prevent COVID-19 Disease and Reported Allergic Reactions: Current Evidence and Suggested Approach. *J Allergy Clin Immunol Pract.* 2021;9(4):1423-37. doi: 10.1016/j.jaip.2020.12.047.
14. Joshi R. Incidental finding of skin deposits of corticosteroids without associated granulomatous inflammation: report of three cases. *Indian J Dermatol Venereol Leprol.* 2008;74(1):44-6. doi: 10.4103/0378-6323.38408.
15. Soria A, Baeck M, Goossens A, Marot L, Duveille V, Derouaux AS, Nicolas JF, Tennstedt D. Patch, prick or intradermal tests to detect delayed hypersensitivity to corticosteroids? *Contact Dermatitis.* 2011;64(6):313-24. doi: 10.1111/j.1600-0536.2011.01888.x.
16. Barnes L, Kaya G, Rollason V. Topical corticosteroid-induced skin atrophy: a comprehensive review. *Drug Saf.* 2015;38(5):493-509. doi: 10.1007/s40264-015-0287-7.
17. Niculet E, Bobeica C, Tatu AL. Glucocorticoid-Induced Skin Atrophy: The Old and the New. *Clin Cosmet Investig Dermatol.* 2020;13:1041-50. doi: 10.2147/CCID.S224211.
18. Schoepe S, Schäcke H, May E, Asadullah K. Glucocorticoid therapy-induced skin atrophy. *Exp Dermatol.* 2006;15(6):406-20. doi: 10.1111/j.0906-6705.2006.00435.x.
19. Greenhawt M, Abrams EM, Shaker M, Chu DK, Khan D, Akin C, et al. The Risk of Allergic Reaction to SARS-CoV-2 Vaccines and Recommended Evaluation and Management: A Systematic Review, Meta-Analysis, GRADE Assessment, and International Consensus Approach. *J Allergy Clin Immunol Pract.* 2021;9(10):3546-67. doi: 10.1016/j.jaip.2021.06.006.
20. Vu MT, Nguyen AQ, Nguyen BD, Duong HT, Nguyen QV, Nguyen HH, et al. Utility of skin testing in assessment of post-AZD1222 vaccine (AstraZeneca) allergic reactions: case series in Vietnam. *Asia Pac Allergy.* 2021;11(4):e40. doi: 10.5415/apallergy.2021.11.e40.
21. Radice A, Fassio F, Meucci E, Iorno MCL, Macchia D. Potential culprits for immediate hypersensitivity reactions to BNT162b2 mRNA COVID-19 vaccine: not just PEG. *Eur Ann Allergy Clin Immunol.* 2021;53(5):240-2. doi: 10.23822/EurAnnACI.1764-1489.214.
22. Wolfson AR, Robinson LB, Li L, McMahon AE, Cogan AS, Fu X, Wickner P, Samarakoon U, Saff RR, Blumenthal KG, Banerji A. First-Dose mRNA COVID-19 Vaccine Allergic Reactions: Limited Role for Excipient Skin Testing. *J Allergy Clin Immunol Pract.* 2021;9(9):3308-20.e3. doi: 10.1016/j.jaip.2021.06.010.
23. Greenhawt M, Shaker M, Golden DBK. PEG/Polysorbate Skin Testing Has No Utility in the Assessment of Suspected Allergic Reactions to SARS-CoV-2 Vaccines. *J Allergy Clin Immunol Pract.* 2021;9(9):3321-2. doi: 10.1016/j.jaip.2021.06.025.